

Forrest I. Townsend Jr and Lydia Staggs

Atlas of Skin Diseases of Small Cetaceans



Photo courtesy of Christina Toms

Todd Speakman Photo Editor

Atlas of Skin Diseases of Small Cetaceans

Forrest I. Townsend Jr and Lydia Staggs

Todd Speakman Photo Editor

Book Design

MS Hendrick Design & Photography
mshendrick@comcast.net

On the Cover:

This bottlenose dolphin (*Tursiops truncatus*) calf was located in Pensacola Bay, Florida, one year after a historic flooding event in 2014. Both mom and calf were sighted several months later with a very dark area on top of their heads.

A few months later the dark area was gone and the heads of both animals were pale lacking in the normal grey pigment. This skin condition rapidly progressed toward the caudal end of both mom and calf, covering at least half their bodies. The following month the calf's tissues appeared necrotic and it showed signs of weight loss. The mother was sighted a few months later without her calf, her skin condition was normal. It is unknown if the calf survived.

Etiology remains unknown, but fresh water exposure was suspected.

ISBN: 978-0-578-49642-9

Acknowledgement

From the earliest studies on the health of wild dolphin populations, great strides have been made. These accomplishments would have not have been possible without the efforts of untold numbers of volunteers: dolphin handlers, logistics personnel, scientists, veterinary technicians, and veterinarians.

These projects came with considerable expense, not only from the volunteers who gave of their time, but also through private donations, institutional, corporate, state and federal funding. During these wild dolphin health assessments, the opportunity to teach technicians, handlers, lab personnel, and veterinarians has been very rewarding.

There are many people who have taught me the techniques and methods to safely and competently carry out our research, far too many to name individually, and I am sure I would miss some important individuals. To all of you, thank you for my education.

Special Thanks

This book would not have been possible without the efforts of hundreds of volunteers, veterinarians and scientists. We worked together in many wild dolphin health assessments, these being the largest part of my experience with the various conditions described in the book. I have been mentored by several excellent marine mammal veterinarians over my early years in the field. A special thanks to Dr. Jay Sweeney as my first mentor and strong supporter of my work over the years. I would be remiss if I did not thank two people who were key figures in my early marine mammal career. George Gray, on staff at the Gulfarium Marine Adventure Park, Fort Walton Beach, Florida, often worked side by side with me on the beach with stranded dolphins and whales. Diane Sips, a laboratory technician at the local hospital, was on the beach and assisting in the rehabilitation process. But more importantly, she carefully archived the data and Kodachrome slides/photos of the cases we worked on together for many years. To both of them I owe a great deal of gratitude. I also thank my co-editor, Dr. Lydia Staggs, for her assistance in making this book a reality.

This book is dedicated with great love and affection to my wife, Sally.

TABLE OF CONTENTS

Introduction	6
Contributors	7
Anatomy and Function of the Integument of Cetaceans	10
Skin/Blubber Biopsy Techniques	12
CHAPTER ONE: <i>Viral Disease</i>	
<i>Herpesvirus</i>	16
<i>Papillomavirus</i>	20
<i>Poxvirus</i>	24
CHAPTER TWO: <i>Bacterial Disease</i>	
<i>Erysipelothrix</i>	28
<i>Staphylococcus</i>	30
CHAPTER THREE: <i>Fungal Disease</i>	
<i>Mucromycosis (formally known as Zygomycosis)</i>	34
<i>Paracoccidioidomycosis ceti (formerly known as Lacaziosis or Lobomycosis)</i>	38
CHAPTER FOUR: <i>Protozoan/Algae Disease</i>	
<i>Protozoan Ulcerative Dermatitis</i>	42
<i>Diatoms</i>	46
CHAPTER FIVE: <i>Parasitic Disease</i>	
<i>Penella sp and Cyamids</i>	48
<i>Xenobalanus</i>	50

CHAPTER SIX: Traumatic Disease

<i>Biopsy Scars</i>	52
<i>Boat Propeller Injury</i>	54
<i>Circle Entanglement</i>	56
<i>Cookie Cutter Shark Wounds</i>	62
<i>Dorsal Fin Transmitter Damage</i>	64
<i>Fish Nets Marks</i>	66
<i>Fish Spines in Fluke and tail stock “Fish Whacking”</i>	68
<i>Fishing Line Entanglement Signs</i>	70
<i>Gun Shot Wounds</i>	76
<i>Rake Marks</i>	78
<i>Shark Bite Injury</i>	80
<i>Stingray Spine Injury</i>	86
<i>Strand Feeding</i>	88

CHAPTER SEVEN: Miscellaneous

<i>Emaciation</i>	90
<i>Exposure Dermatitis</i>	92
<i>Freshwater Exposure</i>	94
<i>Hypo-pigmentation</i>	98
<i>Sketetal Malformations (Scoliosis/Kyphosis)</i>	106
<i>Squamous Cell Carcinoma</i>	110

CHAPTER EIGHT: Other Interesting cases

<i>Axillary Burns</i>	112
<i>Birth Marks</i>	112
<i>Deep Water Squid Wounds</i>	113
<i>Hair Follicle Inflammation</i>	114
<i>Remora Wounds</i>	114
<i>Whale Lice</i>	115

Introduction

Beginning in the winter of 1988, I became involved with wild dolphin health assessments in Sarasota Bay, Florida, with Dr. Randall Wells in his long term study of this population of dolphins. At that point, I had been working with Florida's Gulfarium, a small oceanarium in the Florida panhandle, and their dolphins for ten years.

This first experience was exciting and marked the beginning of a long career as a marine mammal veterinarian working with wild dolphin health assessments. The basic science of the work intrigued me; there was a lot to learn. There were skin lesions and diseases associated with managed care dolphins, but there was an abundance of skin lesions in the wild dolphin populations that I was unaware of. So, the seed for this dolphin skin atlas was planted long ago. Over these past years, I have come to recognize many of the common skin lesions in dolphins, both in managed populations and in their wild counterparts. Although the title of this publications indicates "skin diseases", many of the lesions described are traumatic in origin. Many lesions are a result of natural causes but some are human related, intentional and unintentional. There has been a need to publish a reference guide describing an assortment of skin lesions observed in small cetaceans. Questions regarding various skin lesions are commonly asked during wild dolphin health assessments, of stranded cetaceans and dolphins in managed care.

Many of the lesions observed can be diagnosed by their gross appearance. However, for the student, volunteer or novice veterinarian, unfamiliar with typical skin diseases/lesions, the help of an experienced marine mammal individual is often required for the presumptive diagnosis.

With the increased use of photo identification projects along our coastal waters, along with the improvements in digital photography, this atlas is designed to help answer questions regarding the etiology of skin lesions. This skin atlas has the gross appearing lesions to help recognize the disease as well as the proper techniques for a definitive diagnosis. The diseases amenable to treatment are discussed as to the current recommended therapy. When possible, published references are included.

There was a publication in 1983 "Atlas of Skin Disease of the Horse" by Leopoldo Montes and J.T. Vaughan, which encouraged my co-editor and me to attempt to publish a similar book for dolphins. Recognizing the need for this type of publication for dolphin trainers, stranding group volunteers and the veterinary practitioner new to the marine mammal field. We realize our work is far from perfect, but we trust it can be a step in the right direction towards a better understanding of skin and other conditions observed in small cetaceans.

CONTRIBUTORS

Jason B. Allen

*Chicago Zoological Society
Sarasota Dolphin Research Program
Sarasota, Florida*

Brian C. Balmer

*National Marine Mammal Foundation
Charleston, South Carolina*

Sue Barraco

*Virginia Beach Aquarium
Virginia Beach, Virginia*

Ashley Barratclough

*National Marine Mammal Foundation
San Diego, California*

Gregory Bossart

*Georgia Aquarium
Atlanta, Georgia*

Kathleen M. Colegrove

*Zoological Pathology Program
University of Illinois
College of Veterinary Medicine
Brookfield, Illinois*

Alissa Deming

*Dauphin Island Sea Laboratory
Dauphin Island, Alabama*

Bethany M. Doescher

*Sea Life Park
Waimanalo Beach, Hawaii*

Daniel Garcia

*Director of Zoological Operations
Avanqua Oceanografic S.L.
Valencia, Spain*

Kristi Lynn Fazioli

*Environmental Institute of Houston
University of Houston
Houston, Texas*

Forrest Gomez

*National Marine Mammal Foundation
San Diego, California*

Craig A. Harms

*Center for Marine Sciences and Technology
College of Veterinary Medicine
North Carolina State University
Morehead City, North Carolina*

Leslie B. Hart

*College of Charleston
Charleston, South Carolina*

Mike Kinsel

*Zoological Pathology Program
University of Illinois
College of Veterinary Medicine
Brookfield, Illinois*

Barbara Linnehan

*National Marine Mammal Foundation
San Diego, California*

Gretchen Lovewell

*Chicago Zoological Society
Sarasota Dolphin Research Program
Sarasota, Florida*

Molly Martony

*Aquatic Animal Health Program
College of Veterinary Medicine
University of Florida
Gainesville, Florida*

Jenny Meegan

*National Marine Mammal Foundation
San Diego, California*

Hendrik Nollens

Sea World Orlando
Orlando, Florida

Lisa Scarano Quigley

College of Charleston
Charleston, South Carolina

Michael Scott

Inter American Tropical Tuna Commission
La Jolla, California

Cynthia R. Smith

National Marine Mammal Foundation
San Diego, California

Todd Speakman

National Marine Mammal Foundation
Charleston, South Carolina

Lydia A. Staggs

Sea World Orlando
Orlando, Florida

Jay Sweeney

Dolphin Quest
San Diego, California

Forrest I. Townsend, Jr.

Bayside Hospital for Animals
Ft. Walton Beach, Florida

William Van Bonn

Shedd Aquarium
Chicago, Illinois

Michael Walsh

University of Florida
Gainesville, Florida

Randall Wells

Chicago Zoological Society
Sarasota Dolphin Research Program
Sarasota, Florida

Krystan Wilkinson

Chicago Zoological Society
Sarasota Dolphin Research Program
Sarasota, Florida

Eric Zolman

National Marine Mammal Foundation
Charleston, South Carolina

**A Special Thank You To The
Following Photo Contributors:**

Natalia Fraija

Universitat de Valencia, Spain

Secret Holmes

*Gulf World Marine Park
Panama City Beach, Florida*

Steve McCulloch

*Ocean Experience
Key Largo, Florida*

Wayne Mcfee

*NOAA/NCCOS
Charleston, South Carolina*

Lauren Noble

*NOAA Affiliate
Southeast Fisheries Service Center
Pascagoula, Mississippi*

Roberto Sanchez

*Dolphin Discovery
Mexico*

Stephanie Schmidt

*Mirage
Las Vegas, Nevada*

Diane Sips

Fort Walton Beach, Florida

Kaye Sparks

Brunswick, Georgia

Christina Toms

*Research Associate
Chicago Zoological Society
Sarasota Dolphin Research Program
Sarasota, Florida*

Anatomy and Functions of the Integument of Cetaceans

Michael Kinsel

Odontocete skin is similar to that of other mammals in structure and function. It is multilayered, with an epidermis, dermis and hypodermis and serves as an environmental barrier, plays an important role in thermoregulation, and is a primary sensory interface with the environment and conspecifics. However, a number of relatively unique structural and functional realities also exist that clearly delineate cetacean skin from that of terrestrial mammals. While dolphin skin is sometimes described as smooth and may even feel so to the touch, in several odontocete species the skin on much of the body in fact possesses regular surface ridges aligned perpendicular or at an oblique angle to the long axis of the body. These ridges are believed important in sensory perception and may have a function in maintenance of laminar flow over the cutaneous surface. Dolphin skin is hairless (besides few rostral vibrissae in the neonate that are lost shortly after birth) and lacks adnexal glands (besides the mammary glands). The skin is highly innervated, particularly in the head, blowhole area, perianal and genital slit where tactile sensitivity has been shown to be greatest and similar to that of human fingertips and lips. Cutaneous contact sensation has been suggested as providing feedback on velocity and turbulent flow and thus assisting in locomotion, and is important in communication.

The epidermis in various odontocete species ranges from approximately 2.5 to 9 mm thick. Thickness also varies by age and anatomic location. The thinnest epidermis is found at the eyelid with thickest regions ventrally and at the rostrum. The epidermis has numerous rete pegs that interdigitate with the dermal papillae. As a result, the epidermis at the apex of dermal papillae is only 20-50% of the thickness of that at the deep terminus of the rete peg. Nomenclature and identification of epidermal layers vary in historical and recent literature, though agreement exists that layers are reduced or simplified in comparison to terrestrial species. Aligned along the basement membrane is a single layer of germinal or basal cells (*Stratum basale* or *S. germinativum*), followed by numerous layers of large polygonal cells alternately ascribed as the *Stratum spinosum*, *S. intermedium* or both, followed by 10-15 layers of flattened cells known as the *Stratum externum*. These outer layers are not synonymous with the familiar anuclear keratinized outer skin layers of terrestrial

mammals and usage of the term *Stratum corneum* is thus misleading and discouraged. Melanocytes and dendritic cells are present. Given the extensive folding of the basal epidermis, high numbers of germinal cells are present and production rate and capacity are high. Shedding rate of surface *Stratum externum* cells is also high, with Hicks et al estimating 12 layers shed daily. The high shed rate has been suggested as an antifouling mechanism and thus beneficial in locomotion. The high production capacity may be of benefit in wound healing.

Total dermal thickness varies by species and location as for the epidermis. The dermis has regular ridges aligned oblique or parallel to the long axis of the body surmounted by the aforementioned dermal papillae. The precise relationship between the dermal ridges and the epidermal surface ridges is uncertain. The dermis is well vascularized and innervated. Arterioles and venules run parallel to the skin surface in the deeper portions of the dermis. In the papillae are a central arteriole with shunts to venules arrayed at the periphery. Also, in fins and the fluke are parallel plexuses composed of a central artery with multiple surrounding veins that presumably function as a heat exchanger and thus appear important in thermoregulation. Clinically these structures are important as the common site for venipuncture. Structurally, the dermis is composed primarily of collagen but does contain some elastin fibers. At the deep margin, dermal collagen bundles blend into those of the hypodermis and the boundary between the layers can be obscure.

The hypodermis, or blubber, spans between the dermis and underlying skeletal muscle. Blubber is a complex tissue with multiple functions. The blubber layer assists in locomotion via maintenance of streamlined body contour as well as through biomechanical mechanisms. Thermoregulatory benefits include provision of insulation, and at least in some species, brown adipose tissue content for heat generation. Blubber also contributes to buoyancy, is the repository for energy stores, and fatty acid content has even been speculated to play a role in wound healing via antimicrobial activity. Blubber is subdivided into three strata that are composed of varying percentages of connective and adipose tissues, and also have differing fatty acid profiles. The superficial layer has

a high percentage of connective tissue with low numbers of adipocytes; the middle layer is composed primarily of large adipocytes with lesser connective tissue; the deep layer again has a greater connective tissue content and adipocytes tend to be smaller than the middle layer. Brown adipose tissue is localized to the deep layer. The utilization of lipid content for energy is most evident in the middle and deep layers. The superficial layer is relatively metabolically inactive in comparison. This may have functional significance, with superficial blubber serving primary structural (and thereby hydrodynamic) and possibly insulating functions versus energy storage. Regional anatomic differences also exist, with tailstock blubber being metabolically inactive and thought to also serve a locomotor function, versus mid-thorax, where metabolic activity is high and adipocyte size and lipid content can be dynamic.

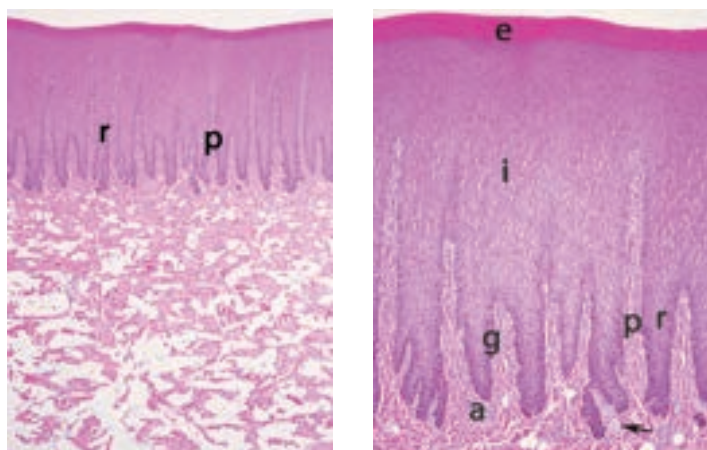


Figure 1: Epidermis, dermis and superficial blubber, Bottlenose dolphin (*Tursiops truncatus*). The epidermis has long rete ridges (r) that interdigitate with dermal papilla (p).

Figure 2: Epidermis, Bottlenose dolphin (*Tursiops truncatus*). Higher magnification again showing rete ridges (r) and dermal papilla. Epidermis is composed of many cell layers with a single layer of germinal cells along the basement membrane (stratum germinativum, g), numerous intermediate layers (stratum spinosum or intermedium, i) and the outer compact layers of the stratum externum (e). The superficial dermis is well vascularized with many small arterioles (a) and has several small nerves (arrow).

REFERENCE

- Carpenter, P. W. (2006). Hydrodynamics of dolphin skin and other compliant surfaces. *Flow Phenomena in Nature* Volume 2, 4, 447–456. <http://doi.org/10.2495/1-84564-095-0/5f>
- Cozzi, B., Huggenberger, H.A., & Oelschläger, H. A. (2017). *General Appearance and Hydrodynamics (Including Skin Anatomy)*. In B. Cozzi, H.A. Huggenberger & H.A. Oelschläger (Eds.), *Anatomy of Dolphins: Insights into Body Structure and Function* (pp.21-31). London: Academic Press.
- Harrison, R.J. & Thurley, K.W. (1974). *Structure of the Epidermis in Tursiops, Dophinus, Orcinus and Phocoena*. In R.J. Harrison (Ed.), *Functional Anatomy of Marine Mammals Volume 2* (pp. 45-70). London: Academic Press.
- Hashimoto, O., Ohtsuki, H., Kakizaki, T., Amou K., Sato, R., Doi, S., Kobayashi, S., Matsuda, A., Sugiyama, M., Funaba, M., Matsuishi, T., Terasawa, F., Shindo, J., & Endo, H. (2015). Brown adipose tissue in cetacean blubber. *PLoS ONE*, 10(2), 1–14. <http://doi.org/10.1371/journal.pone.0116734>
- Hicks, B. D., St. Aubin, D. J., Geraci, J. R., & Brown, W. R. (1985). Epidermal growth in the bottlenose dolphin, *Tursiops truncatus*. *Journal of Investigative Dermatology*, 85(1), 60–63. <http://doi.org/10.1111/1523-1747.ep12275348>
- Kremers, D., Célérier, A., Schaal, B., Campagna, S., Trabalon, M., Böye, M., Hausberger, M., & Lemasson, A. (2016). Sensory Perception in Cetaceans: Part I—Current Knowledge about Dolphin Senses As a Representative Species. *Frontiers in Ecology and Evolution*, 4(May), 1–17. <http://doi.org/10.3389/fevo.2016.00049>
- Koopman, H. N., Pabst, D. A., McLellan, W. A., Dillaman, R. M., & Read, A. J. (2002). Changes in Blubber Distribution and Morphology Associated with Starvation in the Harbor Porpoise (*Phocoena phocoena*): Evidence for Regional Differences in Blubber Structure and Function. *Physiological and Biochemical Zoology*, 75(5), 498–512. <http://doi.org/10.1086/342799>
- Lauriano, E. R., Silvestri, G., Kuciel, M., Zuwała, K., Zacccone, D., Palombieri, D., Alesci, A. & Pergolizzi, S. (2014). Immunohistochemical localization of Toll-like receptor 2 in skin Langerhans' cells of striped dolphin (*Stenella coeruleoalba*). *Tissue and Cell*, 46(2), 113–121. <http://doi.org/10.1016/j.tice.2013.12.002>
- Montie, E. W., Garvin, S. R., Fair, P. A., Bossart, G. D., Mitchum, G. B., McFee, W. E., Speakman, T., Starczak, V.R., & Hahn, M. E. (2008). Blubber morphology in wild bottlenose dolphins (*Tursiops truncatus*) from the Southeastern United States: Influence of geographic location, age class, and reproductive state. *Journal of Morphology*, 269(4), 496–511. <http://doi.org/10.1002/jmor.10602>
- Pabst, D. A. (1996). Morphology of the subdermal connective tissue sheath of dolphins: A new fibre-wound, thin-walled, pressurized cylinder model for swimming vertebrates. *Journal of Zoology*, 238(1), 35–52. <http://doi.org/10.1111/j.1469-7998.1996.tb05378.x>
- Shoemaker, P. A., & Ridgway, S. H. (1991). Cutaneous Ridges in Odontocetes. *Marine Mammal Science*, 7(1), 66–74. <http://doi.org/10.1111/j.1748-7692.1991.tb00551.x>
- Simpson, J.G. & Gardner, M.B. (1972). Comparative Microscopic Anatomy of Selected Marine Mammals. In S.H. Ridgway (Ed.), *Mammals of the Sea* (pp. 298-413). Springfield, IL: Charles C Thomas.
- Stromberg, M. W. (1989). Dermal-Epidermal Relationships in the Skin of the Bottlenose Dolphin (*Tursiops truncatus*). *Anatomia, Histologia, Embryologia*, 18(1), 1–13. <http://doi.org/10.1111/j.1439-0264.1989.tb00575.x>
- Zasloff, M. (2011). Observations on the remarkable (and mysterious) wound-healing process of the bottlenose dolphin. *Journal of Investigative Dermatology*, 131(12), 2503–2505. <http://doi.org/10.1038/jid.2011.220>

SKIN/BLUBBER BIOPSY TECHNIQUES

Cynthia Smith and Forrest Townsend

When obtaining a skin biopsy sample for diagnostic purposes, standardized techniques and protocols should be followed, to include proper skin preparation and local anesthesia. Additionally, sample acquisition methods should be optimized for the diagnostic tests being performed. Prior to performing a skin biopsy, less invasive techniques should be considered in case a skin swab or scraping would be sufficient for the target tests. When skin biopsies are deemed necessary, the following general techniques have been routinely performed. However, specific procedures should be selected or developed by the attending veterinarian for each sample collected, depending on its purpose and the diagnostic tests to be conducted.

Photo-documentation

Prior to and immediately following sampling, close-up photographs should be taken to aid in diagnosis, treatment (if appropriate) and follow-up. Care should be taken to include a frame of reference for lesion and sample size, such as a ruler or standard object (e.g coin).

Local anesthesia

For each procedure, the veterinarian should determine and administer appropriate pain relief. For minor sampling such as core needle biopsies, cold temperature local anesthesia can be considered, which involves placing gauze on the skin surface followed by an ice pack for approximately 5 minutes. For more invasive sampling such as punch and wedge biopsies, local anesthesia should be considered mandatory in most situations due to the abundance of nerves in cetacean skin¹. The local anesthetic solution utilized most often is lidocaine 2% with epinephrine 1:100,000, giving the solution a few minutes to approximately 5 minutes to take full effect. Without epinephrine, deeper biopsies may bleed excessively. Depending on the biopsy type and site, either a ring block or inverted L block should be sufficient. Small gauge needles (<21g) are appropriate for infusion of local anesthesia.

However, needle length is dependent on whether or not blubber is also to be sampled. If so, ultrasound can aid in determining blubber thickness and selecting the appropriate needle length, which is typically 1” or longer. When deeper samples are desired from the dorsal fin, pectoral flipper, or fluke blades, which can be more difficult to penetrate, a Miltex injector should provide enough pressure to locally infuse the area.

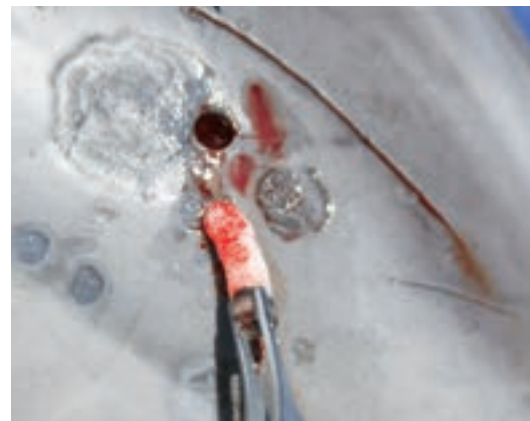Skin preparation

For most skin sampling, routine cleaning with gauze soaked in chlorhexidine solution followed by cleansing with an isopropyl alcohol swab or rinse should be sufficient. Sterile instruments and gloves are always recommended. Care should be taken to avoid overzealous cleaning of surface lesions, which may alter the histologic interpretation of the sample.

Needle biopsy

If core needle biopsies are desired, a sterile 12-16 gauge needle biopsy device can be used to collect skin and blubber samples. Following skin preparation and appropriate local anesthesia, which may be through use of a cold pack as described above, one or more core biopsies can be obtained. Although animals typically don't react to the tissue biopsy itself, the devices may make an audible sound which can startle the animal. Therefore, proper conditioning for managed care dolphins or restraint for wild dolphins is recommended.

Figure 1
This photos shows a biopsy of an out of habitat female dolphin with “normal tissue” included. Interesting the histology of this biopsy reveal intracorneal fungal hyphae suggestive of zygomycetes. Photo by Forrest Townsend.



REFERENCE

1. Ridgway, S. H. (Ed.). (1972). *Mammals of the sea: biology and medicine* (pp. 367). Thomas
2. Gulland, F.M., Dierauf L.A., Whitman, K.L. (Eds.).(2018) *CRC Handbook of Marine Mammal Medicine*, Third Edition. CRC Press. 823-833

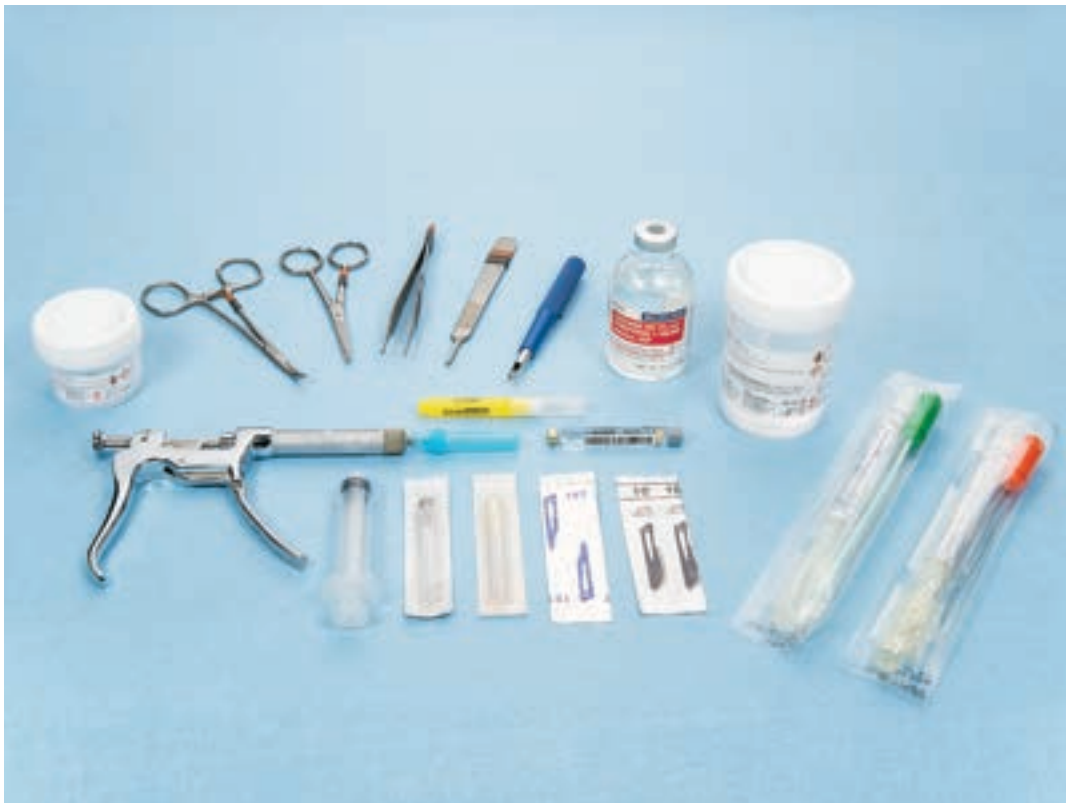

Figure 2: *Standard instruments for sample collection.*

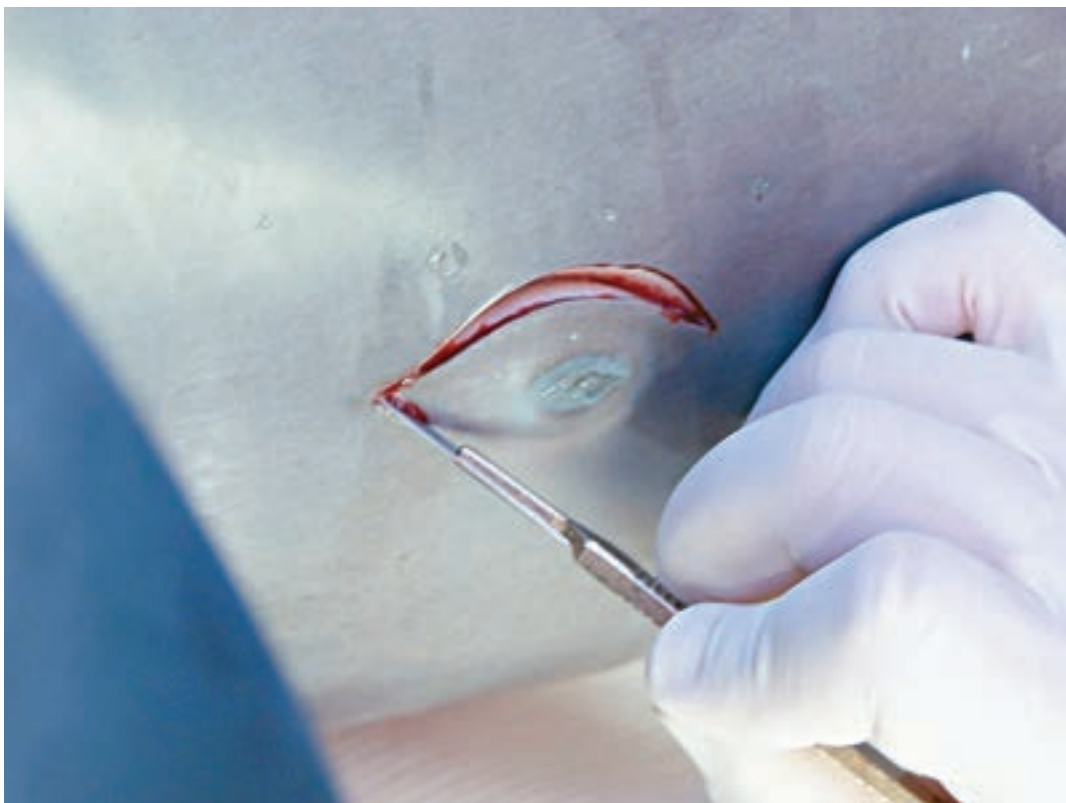


Figure 3: *Wedge biopsy when larger tissue samples are required. Note the local anesthesia injection sites.*

Punch biopsy

Early attempts to recover skin/blubber samples utilized the typical small animal dermal biopsy punches. These devices were problematic, as their shallow depth would not obtain a full thickness biopsy through the bottlenose dolphin's blubber which often measured 16-20mm. Attempting to grasp the sample with tissue forceps and then using a scalpel to free the tissue frequently resulted in inadequate sampling. More recently, a dermal punch biopsy was custom manufactured with a 5mm diameter cut and 20 mm depth that has proven useful for dolphin sampling (see instrumentation photo). Following aseptic skin preparation and adequate infusion of local anesthesia (e.g. ring block of lidocaine 2% with epinephrine 1:100,000), this modified biopsy instrument easily penetrates the skin and blubber layers. The skin and blubber biopsy is then removed with gentle traction and forceps (*photo sequence page 15*). Post-biopsy bleeding is usually very minimal, requiring no therapy. If bleeding does occur, a gauze soaked in ferric subsulfate (Monsel's solution) can be placed in or on the biopsy site to promote clotting.

Wedge biopsy

When more tissue is needed than can be obtained through either core needle or punch biopsies, then a wedge biopsy can be performed. Following aseptic skin preparation and adequate local anesthesia, typically as an inverted "L block", the veterinarian will use

a sterile scalpel to obtain a sample through the full thickness of skin and blubber, usually to the level of the subcutaneous tissue layer. In young and/or underweight animals, care should be taken to avoid cutting through the fascia of the underlying muscle. Ultrasound evaluation of the area prior to the biopsy procedure can help guide the surgeon's scalpel placement and depth to avoid inadvertently cutting these underlying tissue layers. Following tissue removal, a gauze soaked in ferric subsulfate can be placed into the biopsy site and held in place with digital pressure to promote clotting.

Post-sampling

Depending on the diagnostic tests to be performed, samples may be subdivided and stored separately. Tissue samples may be placed in sterile saline, formalin, RNAlater, DMSO, or other solutions. Storage conditions until sample testing depends on the preservatives utilized and testing protocols. Protocols usually include sampling some "normal" tissue for comparison to diseased or affected tissue, particularly when evaluating the tissues histologically. In these cases, working with a pathologist familiar with marine mammal tissues is recommended for protocol selection and sample analysis. Special considerations should be well understood prior to tissue sampling. For example, when skin and blubber samples are collected for persistent organic pollutant analyses, steps should be taken to avoid inadvertently contaminating the sample during collection and processing.

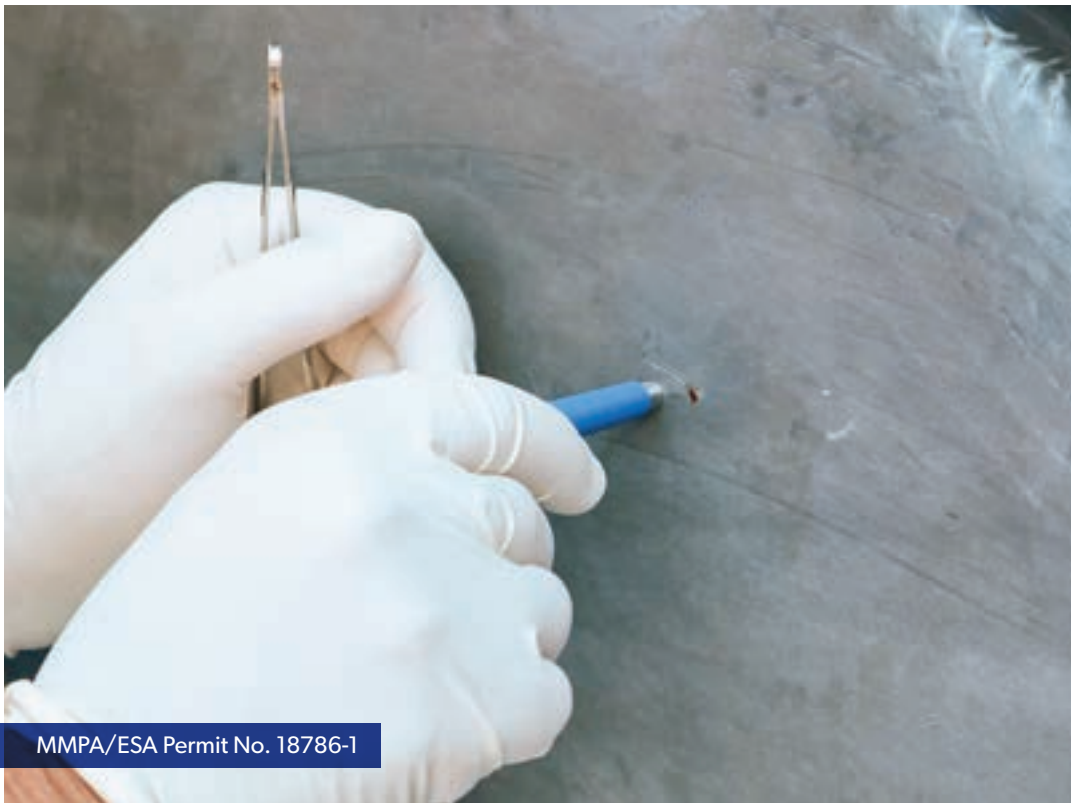

Figure 4: *Biopsy with dolphin biopsy tool note the skin marks to identify the anesthetized site.*

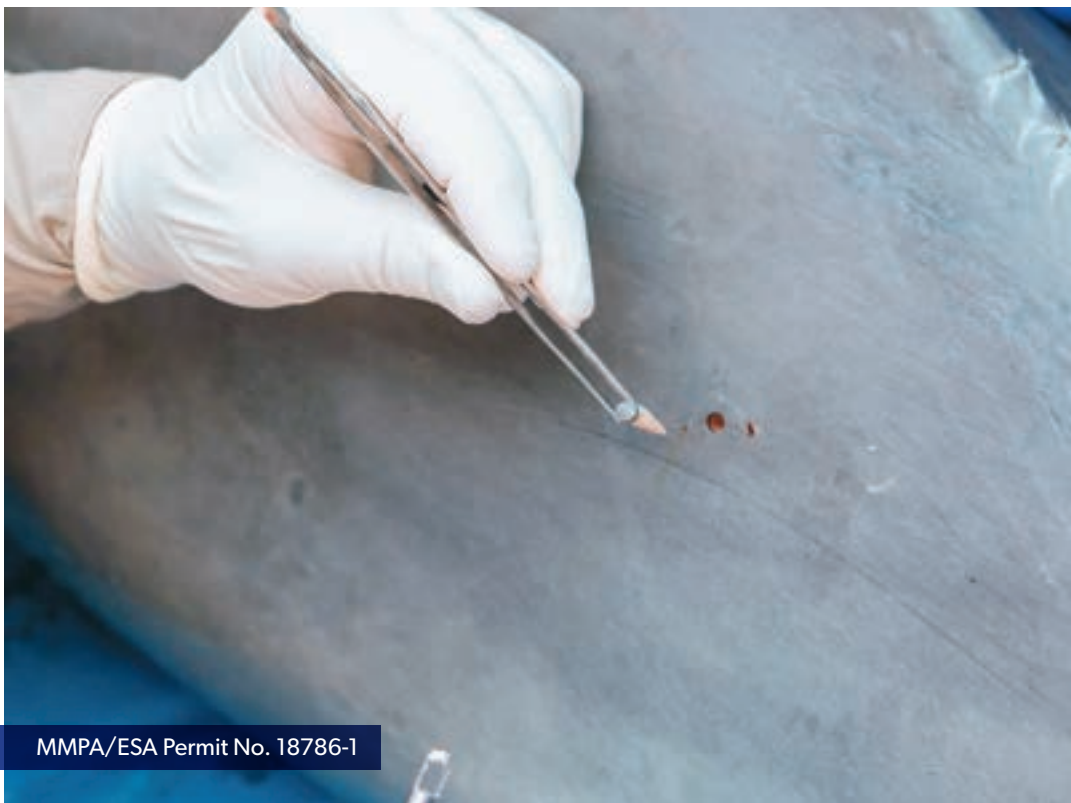

Figure 5: *Recovered punch biopsy sample.*

CHAPTER ONE: VIRAL DISEASE

HERPESVIRUSES

Alissa C. Deming and Kathleen M. Colegrove

Clinical Presentation

Most animal species studied have at least one, but typically multiple, endemic herpesviruses. Overall, herpesviruses are species specific and cannot easily be transmitted between species. Herpesvirus infections most commonly induce clinical disease in young, old and immune compromised hosts. Different types of herpesviruses cause a variety of clinical presentations ranging from non-threatening dermatitis to life-threatening manifestations, such as systemic infections and cancer.

In bottlenose dolphins, there have been 7 herpesviruses described¹⁻⁵ ranging from mild skin lesions, to oral and genital proliferative lesions, to encephalitis and pneumonia. Most clinically relevant is the association between a gammaherpesvirus and squamous cell carcinoma lesions in the oral cavity of bottlenose dolphins. These lesions present as focal or multifocal raised and roughened plaques to sometimes papillary mucosal lesions along the tongue, frenulum or oral mucosa (Fig 1) and progress to ulcerated irregular masses that efface the tissue and result in deviation of the tongue and/or oral pain. These tumors have been documented to metastasize aggressively. A gammaherpesvirus has also been identified in genital lesions of dolphins (*Figure 2 and Figure 3*); however: these lesions are typically benign and have not been associated with aggressive metastasis. The causative versus correlative nature of these herpesviruses are not fully understood and there is speculation that a papillomavirus may also be playing a role in the development of these tumors⁶.

Skin lesions that have been associated with herpesviruses in dolphins result in mild to moderate dermatitis and are most often self-limiting. A report of a stranded juvenile bottlenose dolphin with hyperproliferative skin on the rostrum (*Figure 4*) and multifocal 1-3mm, spherical, firm, black papules along the body and dorsal fin, which progressed to superficial, gray erosions and resolved slowly

overtime with no anti-viral treatment, was found to contain herpesvirus inclusions and was positive for a novel alphaherpesvirus². A case of disseminated herpesvirus infection in a female bottlenose dolphin calf resulted in death, had skin lesions that include unique alphaherpesviruses in addition to a variety of tissues that also contained herpesvirus inclusion bodies and were herpesvirus PCR positive¹. The skin lesions were 0.5 to 2cm in diameter ulcerations on the rostrum and dorsal fin. In this case, the primary cause of death was the result of the systemic herpesvirus infection causing pneumonia and encephalopathy, and not directly associated with the skin lesions.

Histopathology/Diagnostics

Biopsies from suspected skin, oral or genital lesions can be evaluated histologically or with electron microscopy for herpetic inclusion bodies (*Figure 3*). Additionally, frozen tissue biopsy, swabs or collection of fluid from lesions can be tested for the presence of herpesviruses using consensus PCR primers⁵. If the consensus PCR is positive, sequencing is recommended to help identify the type of herpesvirus present.

Herpesvirus shedding is often intermittent and not well understood. For example, it may be possible to screen for herpesvirus during routine examination or pre-shipment testing in a genital swab and have a negative result because the virus is dormant, then later have the same animal be positive due to active viral shedding or lesion development. Thus, herpesvirus screening, particularly negative results, must be interrupted with care.

Treatment

Treatment for viral infections in cetaceans is limited and no direct anti-viral treatment in dolphins has been documented. Typically, following primary infection of a host, herpesviruses lay dormant in either peripheral nerves or white blood cells. If the host becomes stressed, immune compromised, reaches advanced age




Figure 1: A raised, roughened, plaque-like early oral lesion associated with gammaherpesvirus.
Photo by Todd Speakman/NOAA

or other less understood triggers occur, there is risk of viral recrudescence. This can result in various disease presentations, ranging from rashes and blisters to cancer depending on the herpesvirus type. Supportive care and treatment with antimicrobials for any secondary bacterial or fungal infections is recommended.

Treatment of oral squamous cell carcinoma ranges from laser or cryotherapy to debulking or radical resection. Additionally, various attempts at using chemotherapeutics have been tried including

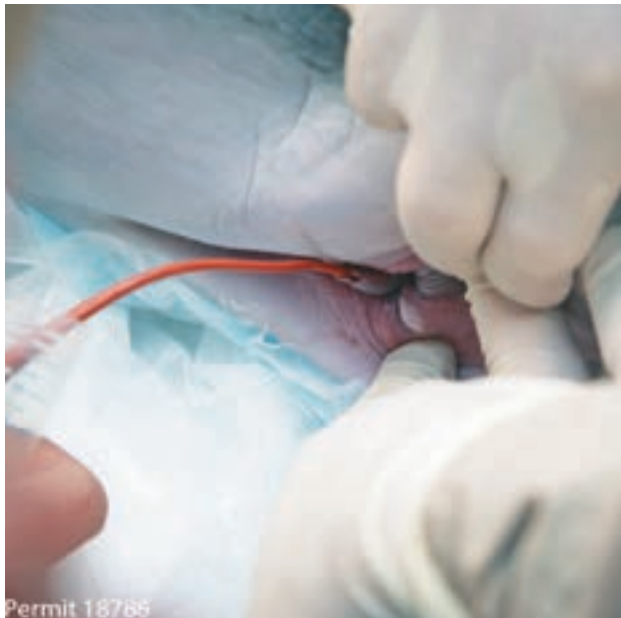

Figure 2: Small, white, plaque-like lesion on the genital mucosa of a male bottlenose dolphin. Photo by Todd Speakman/NOOA.

intralesional Carboplatin⁷, topical 5-Fluorouracil and systemic retinoid therapy (Acitretin)⁸, and a combination of piroxicam with doxycycline⁹ to help prevent regrowth or progression of the cancer, however efficacy of these treatments is often short term and do not commonly result in the resolution of the disease.

Zoonotic Potential

Herpesviruses are very species specific. Zoonotic transfer between a dolphin and a human is not possible and has never been documented.

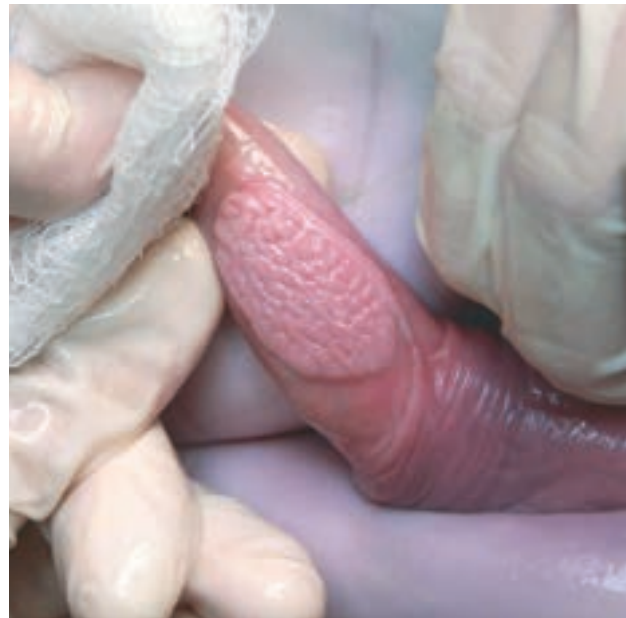

Figure 3: Large, raised, papillomatous lesion on the penis of a male bottlenose dolphin. Photo by Lydia Stagg.

REFERENCE

- Blanchard T., N. Santiago, T. Lipscomb, R. Garber, W. McFee, and S. Knowles. 2001. Two novel alphaherpesviruses associated with fatal disseminated infections in Atlantic bottlenose dolphins. *J Wildl Dis* 37:297-305.
- Manire C., K. Smolarek, C. Romero, M. Kinsel, T. Clauss, and L. Byrd. 2006. Proliferative dermatitis associated with a novel alphaherpesvirus in an Atlantic bottlenose dolphin (*Tursiops truncatus*). *J Zoo Wildl Med* 37:174-81.
- Smolarek Benson K., C. Manire, R. Ewing, J. Saliki, F. Townsend, B. Ehlers, and C. Romero. 2006. Identification of novel alpha- and gammaherpesviruses from cutaneous and mucosal lesions of dolphins and whales. *J Virol Methods* 136:261-6.
- Maness H., H. Nollens, E. Jensen, T. Goldstein, S. LaMere, A. Childress, J. Sykes, J. St Leger, G. Lacave, F. Latson, and J. Wellehan. 2011. Phylogenetic analysis of marine mammal herpesviruses. *Vet Microbiol* 149:23-9.
- VanDevanter D., P. Warrener, L. Bennett, E. Schultz, S. Coulter, R. Garber, and T. Rose. 1996. Detection and analysis of diverse herpesviral species by consensus primer PCR. *J Clin Microbiol* 34:1666-71.
- Rehtanz, M., G. Bossart, P. Fair, J. Reif, S. Ghim, and A. Jensen. (2012). Papillomaviruses and herpesviruses: who is who in genital tumor development of free-ranging Atlantic bottlenose dolphins (*Tursiops truncatus*)? *Vet Microbiol* 160:297-304.
- McKinnie J., S. Dover, G. Ogilvie, and G. Bossart. 2001. Treatment of Oral Squamous Cell Carcinoma in an Atlanta Bottlenose Dolphin (*Tursiops truncatus*). *Abstr. Proc. Annu. Int. Assoc. Aquat. Anim. Med.*, Tampa, Florida, USA.
- Todd L. Schmitt, Thomas H. Reidarson, Judy St. Leger, Hendrik H. Nollens, Greg K. Ogilvie, David R. Proulx. 2010. Medical, Surgical and Radiation Therapy of an Oral Squamous Cell Carcinoma in an Atlantic Bottlenose Dolphin (*Tursiops truncatus*). *Abstr. Proc. Annu. Int. Assoc. Aquat. Anim. Med.*; Tampa, Florida, USA.
- March D., D. Blyde, G. Bossart, A. Begg, D. Taylor, and V. McClure. 2016. Piroxicam and doxycycline treatment for an oral squamous cell carcinoma in an inshore bottlenose dolphin (*Tursiops aduncus*). *Aust Vet J* 94:203-207.



Figure 4. (Manire et al. 2006): Rostrum of a stranded juvenile bottlenose dolphin showing hyperproliferative skin associated with an alphaherpesvirus. Photo by Dr Charles Manire.

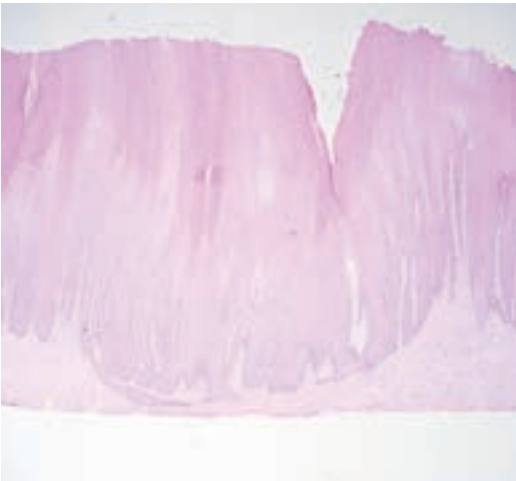

Figure 5. H&E of oral papilloma in an adult bottlenose dolphin with hyperproliferation but no evidence of invasion. Photo by Katie Colegrove.

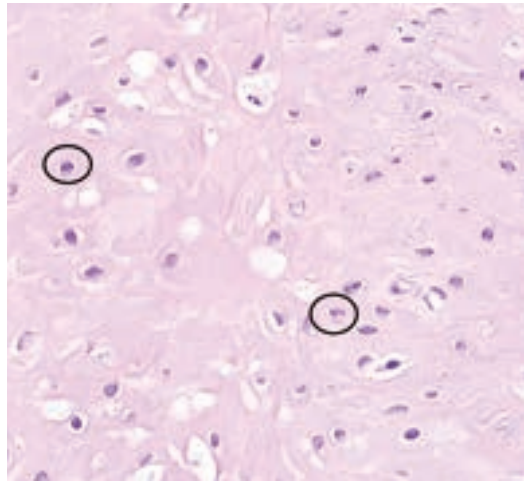


Figure 6: H&E close-up of oral lesion showing herpesvirus inclusions (black circles). Photo by Katie Colegrove.

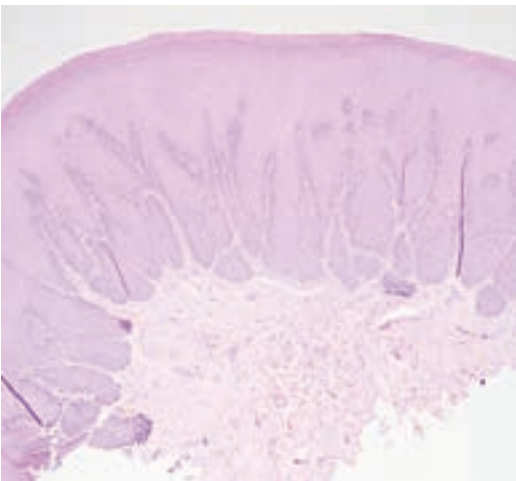


Figure 7. H&E of oral papilloma in an adult bottlenose dolphin with hyperproliferation but no evidence of invasion. Photo by Katie Colegrove.

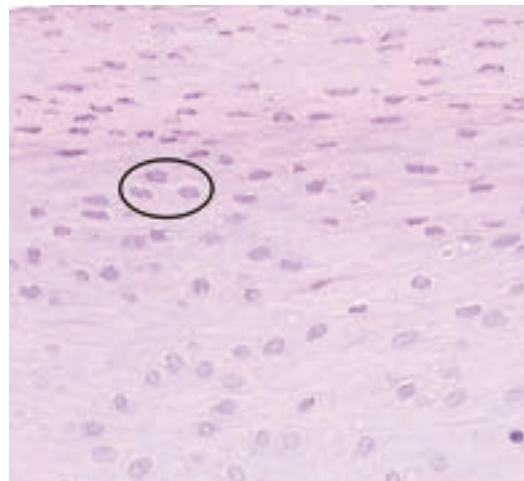


Figure 8. H&E close-up of genital lesion showing herpesvirus inclusions (black circles). Photo by Katie Colegrove.

PAPILLOMAVIRUS

Forrest Gomez and Greg Bossart

Papillomaviruses (PV) are small, intranuclear non-enveloped, double stranded DNA viruses from the family Papillomaviridae.^{1,2} Over 200 unique PV types have been identified in animals and humans.² These viruses can cause proliferation of the stratified squamous epithelium resulting in tumors of the mucosa and skin.^{1,2} These tumors include benign cutaneous, lingual, and genital sessile plaques and verrucoid papillomas.^{1,3,4} Less frequently, tumors induced by certain PV genotypes can persist and progress to invasive carcinomas in other species.^{1,3,4} It is important to note PVs have been detected in clinically normal genital mucosa and skin.⁵ Additionally, not all papillomas are viral in origin and not all animals with serologic evidence of PV infection have tumors.^{6,7,8,9} Horizontal transmission is the most likely route of infection.^{9,10}

Clinical Presentation

Lesions associated with PVs can be solitary or multiple and can progress in size over time.^{7,11} Genital PVs cause slightly raised, oval, irregularly surfaced warts that are white, grey, black or pink.^{4,12,13} Genital lesions are on the external mucosa of both male and female dolphins, as well as on the penis.^{4,7} Oral tumors occur on the anterodorsal aspect of the tongue and/or on the frenulum.^{4,7} Cutaneous warts can progress to a large size and are raised with a smooth or velvety surface.^{1,6} Bloodwork in bottlenose dolphins with oral papillomas can show hypoferrremia, hyperglobulinemia and hyperalphaglobulinemia.¹⁰ These changes are most likely associated with an acute-phase inflammatory response and up-regulated humoral and innate immunity secondary to tumors or the viruses associated with the tumors.¹⁰ Lesions usually regress spontaneously over time.^{1,4} In bottlenose dolphins (*Tursiops truncatus*), a co-occurrence of squamous

cell carcinoma (SCC) and benign papillomas has been noted in oral lesions, suggesting neoplastic transformation might occur.^{4,10}

Diagnosis

Papillomas are characterized by gross and histological features. Lingual and genital mucosal lesions appear as sessile papillomas, or plaques, made of uniformly proliferating keratinocytes and dysplastic keratinocytes with elongation of dermal papillae.^{11,8} Keratinocytes may resemble koilocytes of terrestrial mammals infected with PV by having vacuolated cytoplasm and central or eccentric round vesicular nuclei.¹¹ Confirmation and typing of dolphin PV can be done using PCR, virus amplification, cloning and sequencing.^{2,4,7,11,12,13} Novel PVs in bottlenose dolphins, to include TtPV1-9, have recently been described and have been shown to be associated with genital papillomatosis.^{5,8,13,14,15} Herpesviruses (HV) have also been isolated in papillomas, making it unclear as to what role coinfection might play in lesion pathogenesis.^{4,8,9,16} A viral hit and run mechanism, or PV integration into the hosts genome could cause difficulty with detection using standardized tests, so it is important not to assume that the virus present is the initiator.¹⁶ To date a definitive etiologic agent has not been identified in SCC in bottlenose dolphins, and the extent to which HVs and PVs may cooperate to transform cells remains an area of intense debate.^{8,16}

Treatment

There is no specific treatment for papillomas or PV infection.⁴

Zoonotic Potential

PVs are usually host and tissue site specific and are not easily transmitted between species.^{1,8,11}

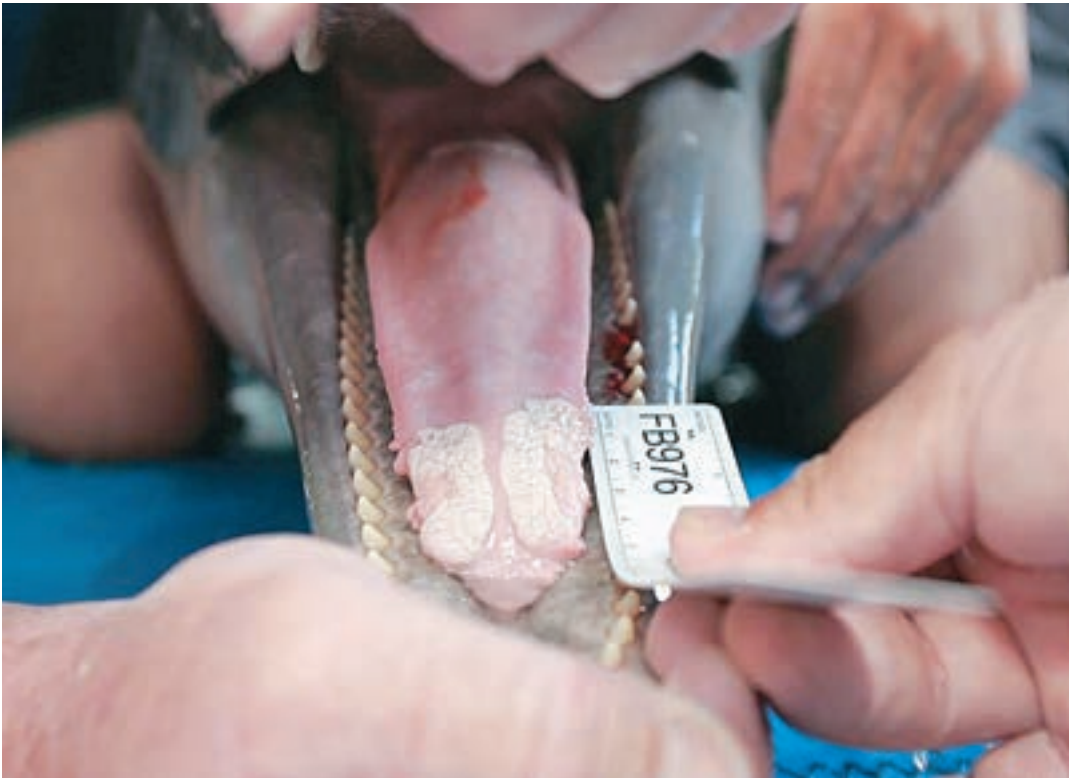

Figure 1: A typical oral sessile papilloma of an Atlantic bottlenose dolphin which may or may not be associated with a papillomavirus and/or herpesvirus. Photo by Greg Bossart. Collected under National Marine Fisheries Service Scientific Research Permit No. 998-167.

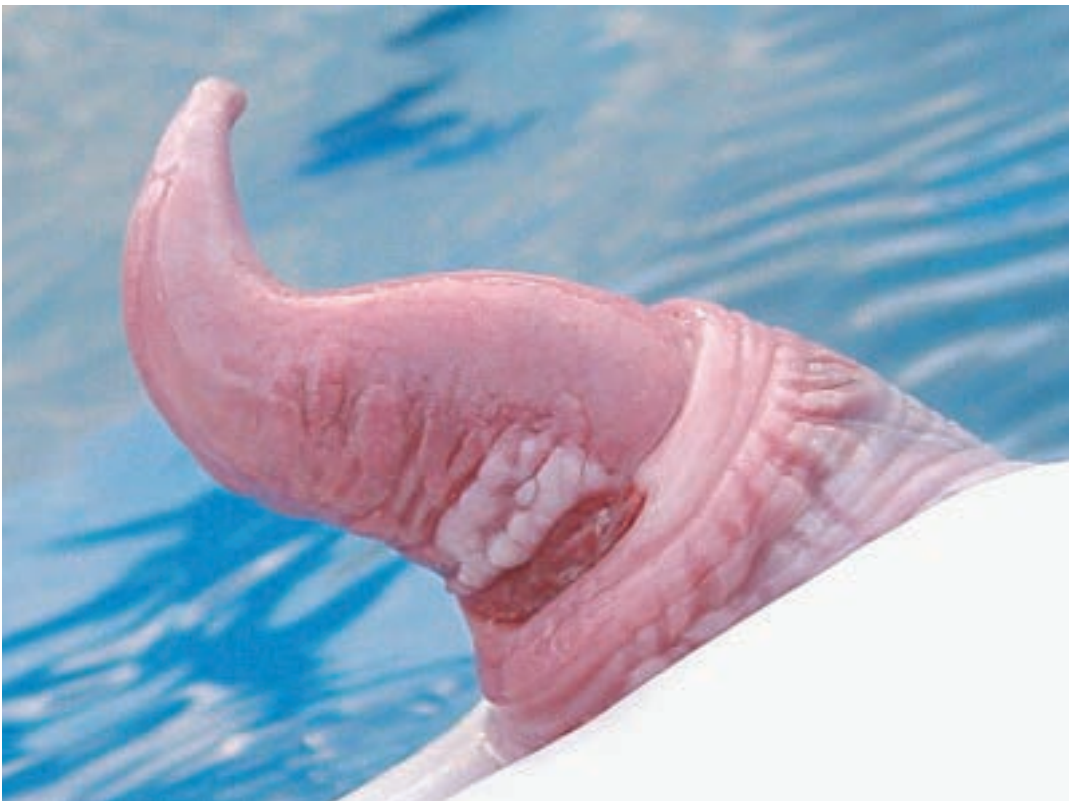

Figure 2: A typical genital sessile papilloma of an Atlantic bottlenose dolphin which may or may not be associated with a papillomavirus and/or herpesvirus. Photo by Daniel Garcia, Fundación Oceanogràfic

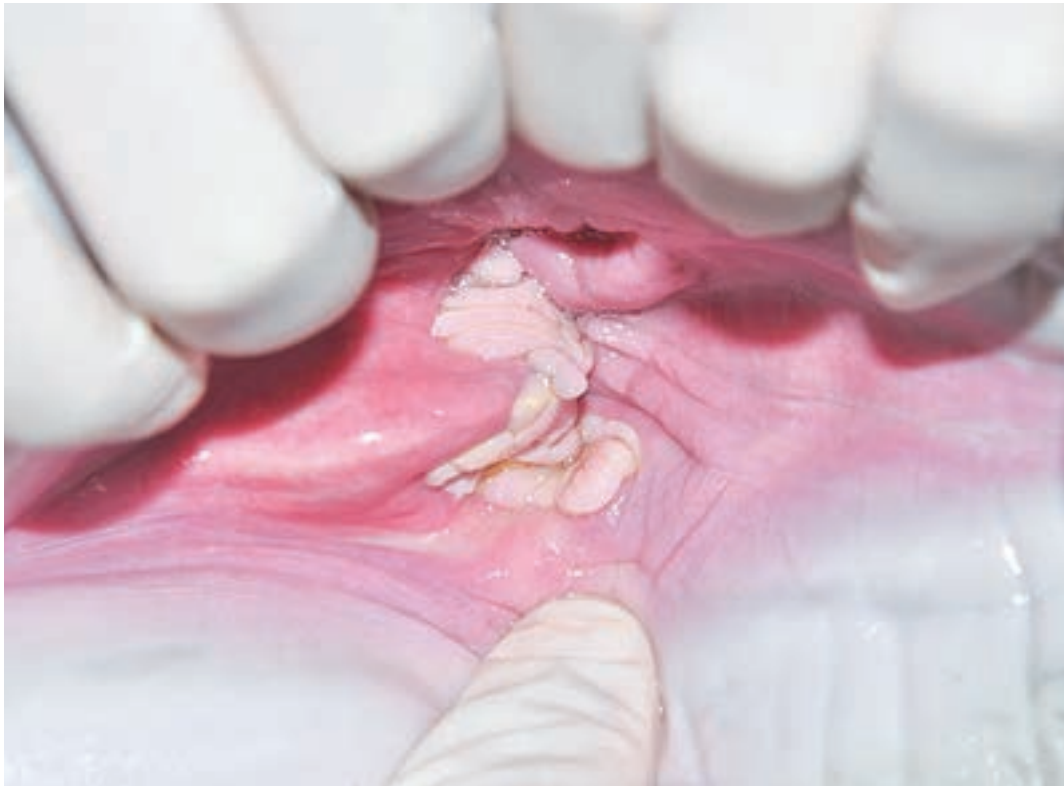

Figure 3: *A typical genital sessile papilloma on the internal mucosa of a female Atlantic bottlenose dolphin which may or may not be associated with a papillomavirus and/or herpesvirus. Photo by Daniel Garcia, Fundación Oceanogràfic*




Figure 4: *A typical cutaneous verrucoid papilloma of an Atlantic bottlenose dolphin which may or may not be associated with a papillomavirus and/or herpesvirus. Photo by Daniel Garcia, Fundación Oceanogràfic*

REFERENCE

1. Van Bresseem, M.F., Kastelein, R.A., Flament, P., Orth, G. (1999) Cutaneous Papillomavirus Infection in a Harbor Porpoise (*Phocoena phocoena*) From the North Sea. *Veterinary Record*. 144: 592-593.
2. Van Bresseem, M.F., Cassonnet, P., Rector, A., Desaintes, C., Van Waerebeek, K., Alfaro-Shigueto, J., Van Ranst, M., Orth, G. (2007). Genital Warts in Burmeister's Porpoises: Characterization of *Phocoena spinipinnis* Papillomavirus Type 1 (PsPV-1) and Evidence for a Second, *Distantly Related* PsPV. *Journal of General Virology*. 88: 1928–1933.
3. Maclachlan, N.J., Dubovi, E.J., Barthold, S.W., Swayne, D.F., Winton, J.R. (2016) *Fenner's Veterinary Virology: Fifth Edition*. Elsevier Inc.
4. Bossart, G.D., Ghim, S.J., Rehtanz, M., Goldstein, J., Varela, R., Ewing, R., Fair, P. et al. (2005). Orogenital neoplasia in Atlantic bottlenose dolphins (*Tursiops truncatus*). *Aquatic Mammals*. 31: 473-480.
5. Robles-Sikisaka, R., Rivera, R., Nollens, H.H., St. Leger, J., Durden, W.N., Stolen, M., Burchell, J., Wellehan, F.X.J. (2012). Evidence of Recombination and Positive Selection in Cetacean Papillomaviruses. *Virology*. 427(2): 189-197.
6. Bossart, G.D., Cray, C., Solorzano, J.L., Decker, S.J., Cornell, L.H., Altman, N.H. (1996). Cutaneous Papillomavira-like Papillomatosis in a Killer Whale (*Orcinus orca*). *Marine Mammal Science*. 12: 274-281.
7. Bossart, G.D., Fair, P., Schaefer, A.M., Reif, J.S. (2017). Health and Environmental Risk Assessment Project for Bottlenose Dolphins *Tursiops truncatus* From the Southeastern USA. *Diseases of Aquatic Organisms*. 125: 141–153.
8. Bossart, G.D., Duignan, P.J. (2018). Emerging Viruses in Marine Mammals. *CAB Reviews*. 13(052). DOI: 10.1079/PAVSNNR2019 13052
9. Rehtanz, M., Ghim, S., McFee, W., Doescher, B., Lacave, G., Fair, P.A., Reif, J.S., Bossart, G.D., Jenson, A.B. (2010). Papillomavirus Antibody Prevalence in Free-Ranging and Captive Bottlenose Dolphins (*Tursiops truncatus*). *Journal of Wildlife Diseases*. 46: 136-145.
10. Bossart, G.D., Romano, T.A., Peden-Adams, M.M., Rice, C.D., Fair, P.A., Goldstein, J.D., Kilpatrick, D., Cammen, K., Reif, J.S. (2008). Hematological, Biochemical, and Immunological Findings in Atlantic Bottlenose Dolphins (*Tursiops truncatus*) with Orogenital Papillomas. *Aquatic Mammals*. 34: 166-177.
11. Gulland, F.M., Dierauf, L.A., Whitman, K.L. (Eds.). (2018). *CRC Handbook of Marine Mammal Medicine*. Third Edition. CRC Press. Pp. 351-353.
12. Gottschling, M., Bravo, I.G., Schulz, E. Bracho, M.A., Deaville, R., Jepson, P.D., Van Bresseem, M.F., Stockfleth, E., Nindl, I. (2011). Modular Organizations of Novel Cetacean Papillomaviruses. *Molecular Phylogenetics and Evolution*. 59: 34-42.
13. Rehtanz, M., Ghim, S., Rector, A., Van Ranst, M., Fair, P.A., Bossart, G.D., Jenson, A.B. (2006). Isolation and Characterization of the First American Bottlenose Dolphin Papillomavirus: *Tursiops truncatus* Papillomavirus Type 2. *Journal of General Virology*. 87: 3559–3565.
14. Rodrigues, T.C.S., Subramaniam, K., Cortés-Hinojosa, G., Wellehan, J.F.X., Ng, T.F.F., Delwart, E., McCulloch, S.D., Goldstein, J.D., Schaefer, A.M., Fair, P.A., Reif, J.S., Bossart, G.D., Waltzek, T.B. (2018). Complete Genome Sequencing of a Novel Type of Omikronpapillomavirus 1 in Indian River Lagoon Bottlenose Dolphins (*Tursiops truncatus*). *Genome Announcements*. 6(17), e00240-18. 10.1128/genomeA.00240-18.
15. Rector, A., Stevens, H., Lacave, G., Lemey, P., Mostmans, S., Salbany, A., Vos, M., Doorslaer, K.V., Ghim, S., Rehtanz, M., Bossart, G.D., Jenson, A.B., Van Ranst, M. (2008). *Genomic Characterization of Novel Dolphin Papillomaviruses Provides Indications for Recombination Within the Papillomaviridae*. *Virology*. 378: 151-161.
16. Rehtanz, M., Bossart, G.D., Fair, P.A., Reif, J.S., Ghim, S., Jenson, A.B. (2012). Papillomaviruses and Herpesviruses: Who is Who in Genital Tumor Development of Free-Ranging Atlantic Bottlenose Dolphins (*Tursiops truncatus*)? *Veterinary Microbiology*. 160: 297–304.

POXVIRUSES/ TATTOO SKIN DISEASE

Forrest I. Townsend, Jr.

Numerous small cetaceans can be infected with skin lesions from poxvirus. These include common bottlenose dolphins (*Tursiops truncatus*), Atlantic white-sided dolphins (*Lagenorhynchus acutus*), Dusky dolphins (*Lagenorhynchus obscurus*), long-beaked common dolphins (*Delphinus capensis*), Burmeister's porpoises (*Phocoena spinipinnis*) and others.¹

Clinical Presentation

A variety of skin lesions can be observed with cetacean poxvirus which causes "tattoo skin disease". These are often referred to as "pinhole", "ring", "circle" or "tattoo" in appearance. Pinhole lesions often appear as multiple stippled skin lesions, light grey in color, with dark centers or borders. In the acute presentation, palpable, slightly raised lesions may be observed, but these lesions become smooth in later stages. Ring and tattoo lesions are solitary 0.5 to 3 cm lesions which are round or elliptical in appearance.¹ The tattoo lesion may be a consolidation of the pinhole lesions and can be very interesting in design. Often the lesions appear on the dorsal surfaces of the cetaceans, involving the head, dorsal fin, pectoral fins, and the fluke. It is not unusual for these viral lesions to be associated with "rake marks". Pox lesions are without morbidity and may persist for some time. However, extensive pox lesions have been reported to have fatal outcomes.⁵ This skin disease has been commonly observed in

wild populations and dolphins in managed care. There may be underlying disease processes or environmental factors contributing to the onset of dolphin pox which need to be investigated.

In his 2018 keynote presentation at the International Association of Aquatic Animal Medicine in Long Beach, California, Dr. Sam Ridgway commented on dolphin pox/ tattoo skin disease. He said neuroscientist believed "the skin was a map of the brain". He also referred to the numerous variety of interesting presentations these tattoo lesions present on the skin of dolphins, indicating maybe more than one strain of pox virus is involved. Ending with "someone should study this disease in more depth."

Histopathology /Diagnostics

A presumptive diagnosis is usually obvious from the typical skin lesions observed. Definitive diagnosis requires skin biopsy and histological examination.

Treatment

There is no specific therapy for dolphin pox. Investigating other systemic disease or environmental stressors should be considered.

Zoonotic potential

Unlike Seal Pox, Dolphin pox virus is not zoonotic to humans.⁶

REFERENCE

- Geraci, J.R., Hicks, B.D. and St. Aubin, D.J. (1979) Dolphin pox: a skin disease of cetaceans. *Canadian Journal of Comparative Medicine* 43: 399-404.
- Smith, A.W., Skilling, D.E., Ridgway, S.H. and Fenner, C.A. (1983) Regression of cetacean tattoo lesions concurrent with conversion of precipitin antibody against a poxvirus. *Journal of the American Veterinary Association* 183: 1219-1222.
- Dierauf, L.A. and Gulland F.D. editors (2001) *Marine Mammal Medicine, second edition*: 286-289.
- Van Bresse M.F., Van Warebeek K. and Bennett M. (2006) Orthopoxvirus neutralizing antibodies in small cetaceans from the Southeast Pacific. *LAJAM* 5(1): 49-54, June 2006.
- Sweeney, J.C., and S.H. Ridgway. 1975. Common diseases of small cetaceans. *Journal of the American Veterinary Medical Association* 167: 533-540.
- Van Bresse M.F., J.A. Raga, G. Di Guardo et al. 2009a. Emerging infectious diseases in cetaceans worldwide and the possible role of environmental stressors. *Diseases of Aquatic Organisms* 86: 143-157



Figure 1: *Typical presentation of pox virus on the head of a common bottlenose dolphin.*
Photo by Forrest Townsend.



Figure 2: *Wild dolphin with pox lesions. Note the trauma to the dorsal fin, and hypopigmentation that can occur. Permit number: MMPA Permit No. 779-1633-00. Photo credit: NOAA*



Figure 3. *Tattoo skin lesions. MMPA Permit No. 779-1633-00. Photo credit: NOAA*



Figure 4. *Tattoo skin lesions in a young calf. MMPA Permit No. 779-1633-00
Photo credit: NOAA*



Figure 5. Interesting tattoo skin lesion next to blow hole, also there are whale lice on the blow hole rim.
Photo credit: Dr. Daniel Garcia, Fundaci'on Oceanografic

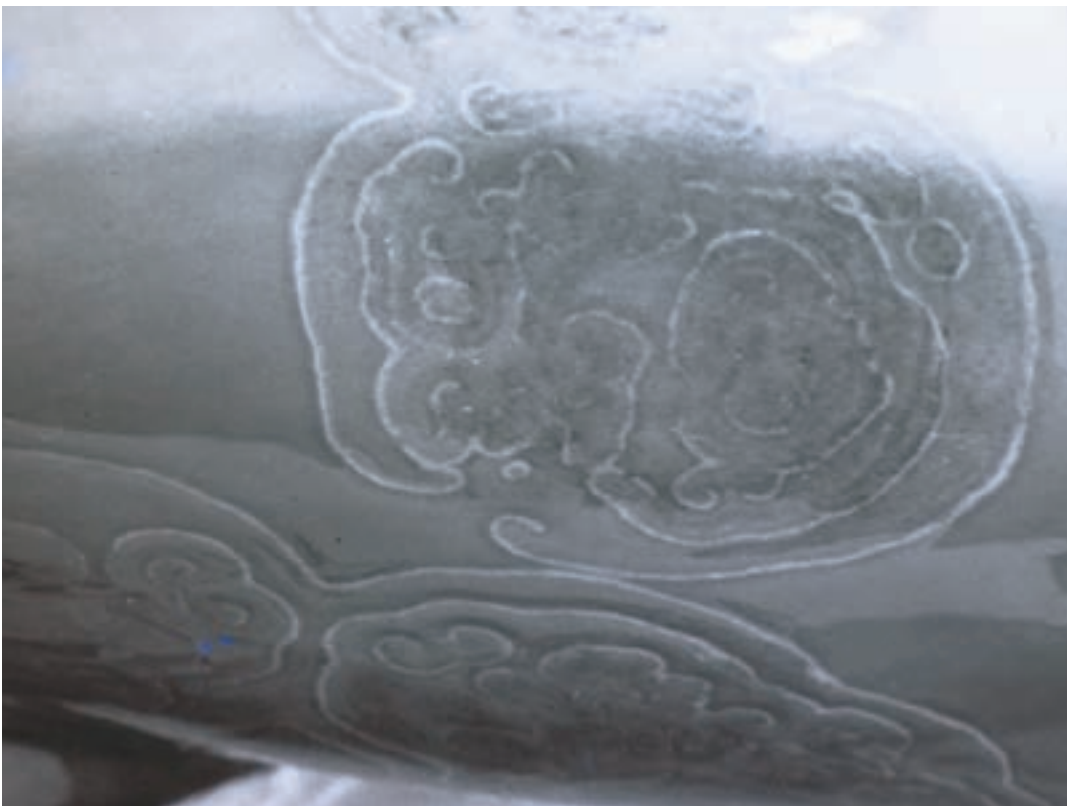

Figure 6. Interesting case of Tattoo Skin Disease. Photo credit Dr. Jay Sweeney

CHAPTER TWO: BACTERIAL DISEASE

ERYSIPELOTHRIX RHUSIOPATHIAE

Forrest I. Townsend, Jr.

Clinical Presentation

This bacteria is a facultative, non-spore-forming, non-acid-fast, small, Gram-positive bacillus. This bacteria is commonly associated with disease in swine and poultry, but also can cause fatal disease in wild and marine mammals in human care. *Erysipelas rhusiopathiae* is a common contaminant culture from the mucus on fish.¹

This disease has two distinct clinical presentations. A skin form and an acute septicemic form. The skin form occurs from dermal infections that result in bulla formation and sloughing of the epidermis (*Figure 2*). The typical rhomboid areas of cutaneous necrosis described in swine (*Figure 1*) may not be present. If left untreated, a fatal outcome can occur.

The peracute septicemia form often results in death unless early antibiotic therapy and supportive is instituted. But, often early clinical signs may be absent or very nonspecific prior to the peracute death; diagnosis is often made at post mortem examination and bacterial culture of the organism. Therefore, *Erysipelas* septicemia should be suspect in any acutely ill cetacean.³ Cases of this disease are reported in both wild and managed care populations.² Many years ago, the use of the available vaccines resulted in death of some dolphins (personal comm. with Dr. Jay Sweeney). In the United States, some facilities have started using a swine *Erysipelothrix rhusiopathiae* vaccine for this disease. An off-label porcine bacterin product was utilized to vaccinate⁵ dolphins against this disease. That study concluded that this vaccination did generate

humoral immunity against this bacteria. The efficiency was influenced by a number of factors, including “booster” immunizations, but not by gender, age or history of previous infections.⁵

Histopathology/Culture

Diagnosis is made from the clinical history and signs, along with culture of this bacteria. It is suggested that the bacteriological laboratory be notified that this bacteria is suspect in the patient. Serology is useful in diagnosis and studying the previous exposure and vaccine response.

Treatment

Penicillin based antibiotics are the preferred therapy, but antibiotics from the class of cephalosporins and fluoroquinolones maybe used. Besides antibiotics other supportive care will be required.

Zoonotic Potential

Public health concerns with this disease in humans causes a localized disease called erysipeloid, although rarely systemic disease can occur. Once thought to be the cause of seal finger, there is new evidence that this disease is caused by one or more mycoplasma. This organism does not respond to treatment with penicillin type antibiotics whereas *Erysipelas* is usually sensitive⁶. In the author’s own experience (FT), during a necropsy of a wild dolphin with definitive diagnosis of central nervous system *Erysipelothrix*, accidentally lacerated a finger on a broken rib through his glove and developed erysipeloid that developed a few days later and responded to ampicillin therapy.

REFERENCE

1. Cowan, Daniel F., House, Carol and James A., (2001) *Handbook of Marine Mammal Medicine, second edition.* 771.
2. Dierauf, L., & Gulland, F. M. (Eds.). (2001). *CRC Handbook of Marine Mammal Medicine, second edition.* CRC press. 316-318.
3. Dunn, J. Lawrence, BRAC John D. and Robeck, Todd R., *Marine Mammal Medicine, p. 316-318, 2001.*
4. Patterson, R.A. 2000, *Proceedings of the Joint Meeting of American Associates of Zoo Veterinarians and International Association for Aquatic Animal Medicines, New Orleans, LA, p. 210.*
5. Nollens, H.H., L.G.Gimenez-Lirola, T.R. Robeck, T.I. Schmitt, S. RiRocco, and T. Opriessnig, 2016, Evaluation of *anti-Erysipelothrix rhusiopathiae* IgG response in bottlenose dolphins *Tursiops truncatus* to a commercial pig vaccine. *Dis Aquat Organ* 121: 249-256.
6. Dierauf, L., Gulland, F.M. and Whitmann K. L. (Eds.). 2018. *CRC handbook of Marine Mammal Medicine, third edition.* CRC press. p.51.



Figure 1. Rhomboid cutaneous lesion on *Tursiops truncatus*. Photo Credit: Dr. Daniel Gracia, Fundació Oceanogràfic

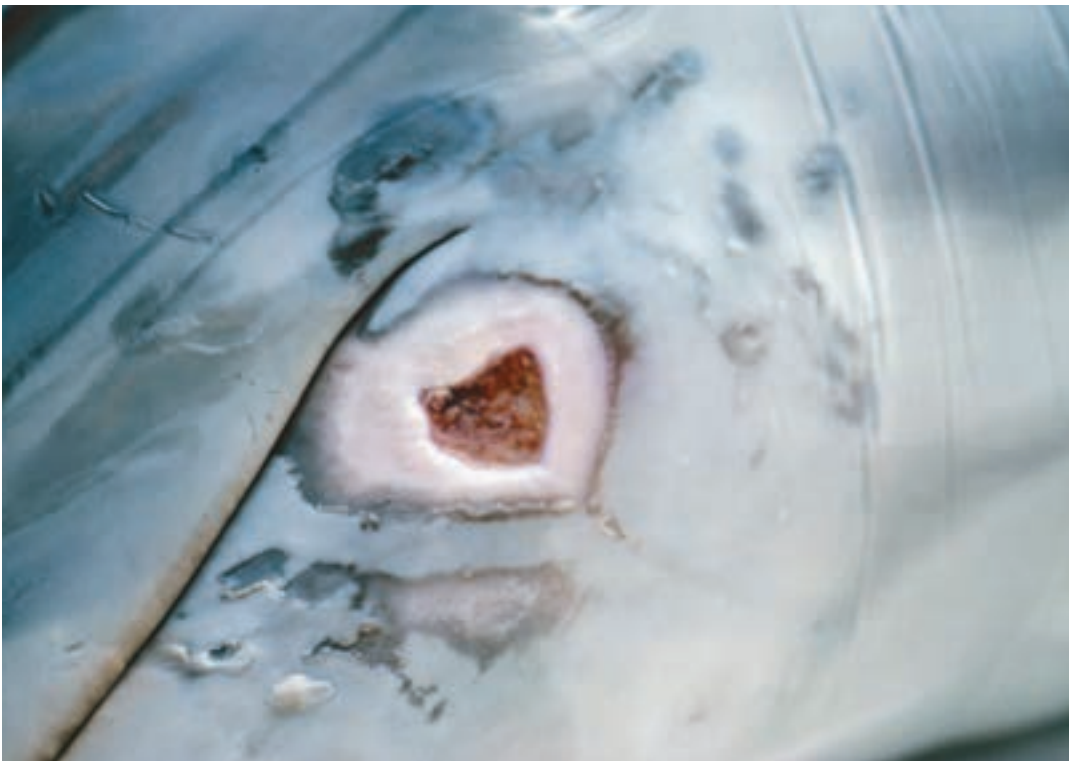

Figure 2. *Erysipelothrix rhusiopathiae* was cultured from this lesion on the lower mandible prior to rupture of the bulla. **NOTE:** This is not the typical “rhomboid” shaped lesion seen in swine. Photo by Forrest Townsend.

STAPHYLOCOCCUS

Barbara Linnehan

Staphylococcus bacteria are Gram-positive, facultatively anaerobic cocci. *Staphylococcus* species are often part of the normal flora of warm-blooded animals, particularly the skin and mucocutaneous surfaces. In cetaceans, *Staphylococcus* species are often cultured from the blowhole, GI tract, or skin.¹⁻⁷ *Staphylococcus delphini* was first described in dolphins in 1988,⁸ isolated from purulent skin lesions and distinct from previously isolated *Staphylococcus* from other species. *Staphylococci* are opportunistic pathogens which can manifest as a wide variety of lesions and disease states, from mild skin infections and abscesses, to lethal bacteremia.

Venn-Watson et al.⁷ identified *Staphylococcus aureus* as the highest risk primary bacterial pathogen in a managed dolphin population, most often associated with pneumonia and septicemia. Many species of Staphylococci have been cultured from wild and managed dolphin populations, including methicillin-resistant *Staphylococcus aureus* (MRSA), *S. epidermidis*, *S. delphini*, *S. hominis*, *S. pasteurii*, and other species.^{4,9-11} These species are also consistent with those cultured from the skin of dolphins at the Navy Marine Mammal Program (San Diego, CA).

Clinical Presentations

As *Staphylococcus spp.* are opportunistic pathogens, there are many presentations of dermal infections seen in dolphins. The most typical presentation is a secondary infection of a primary traumatic or viral lesion and mild ulcerative dermatitis. Figure 1 shows an example of a rough-toothed dolphin (*Steno bredanensis*) who developed a secondary *Staphylococcus* infection after sustaining mosquito bites on the dorsum. Other primary lesions can include rake marks from conspecifics. Staphylococci frequently inhabit the mucocutaneous surfaces, and lesions around the genital slit and oral commissure can also be seen.

Figures 2 and 3 show an example of a juvenile dolphin with waxing and waning *Staphylococcus* ulcerative dermatitis. Multiple biopsies and cultures were taken over the course of a year and suggested a primary viral etiology with secondary bacterial infection (*S. hominis* and *S. pasteurii*). No viral agent was

identified, though poxvirus was suspected. The animal was initially treated with topical chlorhexidine scrub and fresh water rinsing, and later with oral amoxicillin/clavulanic acid as well, which resulted in resolution of ulcerative lesions over time.

In addition to superficial infections, *Staphylococcus spp.* can also cause subcutaneous abscesses. Figure 4 shows a case example of a rough toothed dolphin (*Steno bredanensis*) who developed a large swelling of the ventral cervical lesion following repetitive trauma from rubbing on the side of a pool. A large abscess developed, which resolved following oral antibiotic therapy and flushing of the abscess with catheters and sterile saline. There are also several reports of a “tail stock abscess” syndrome occurring in dolphins in managed facilities, in which there is a subcutaneous abscess in the peduncle, often with secondary boney involvement. One such case report was recently published by Tamura et al. in 2017, which described surgical debridement of a *Staphylococcus aureus* abscess involving the subcutaneous tissues and secondary osteitis of the fourth and fifth caudal vertebrae in a *Tursiops aduncus*. Another example of this syndrome is shown in Figure 5, a juvenile *Tursiops truncatus* undergoing rehabilitation, who developed two large swellings on the right peduncle. The abscesses were drained and the animal was treated with oral ciprofloxacin based on culture and sensitivities of *Staphylococcus aureus*.

Diagnostics

Diagnosis is made from culture and sensitivity testing of lesions. Histopathology of biopsied skin lesions can be variable, dependent upon the underlying etiology.

Treatment

In many cases, topical therapy is sufficient for mild, superficial ulcerative dermatitis, including chlorhexidine or betadine scrubs, fresh water rinsing, and/or application of a triple antibiotic ointment. In more severe cases, such as those with extensive or deep ulcerative dermatitis, or an immunocompromised animal, systemic antimicrobial therapy should be instituted based on culture and sensitivity in combination with topical therapy. Empirical

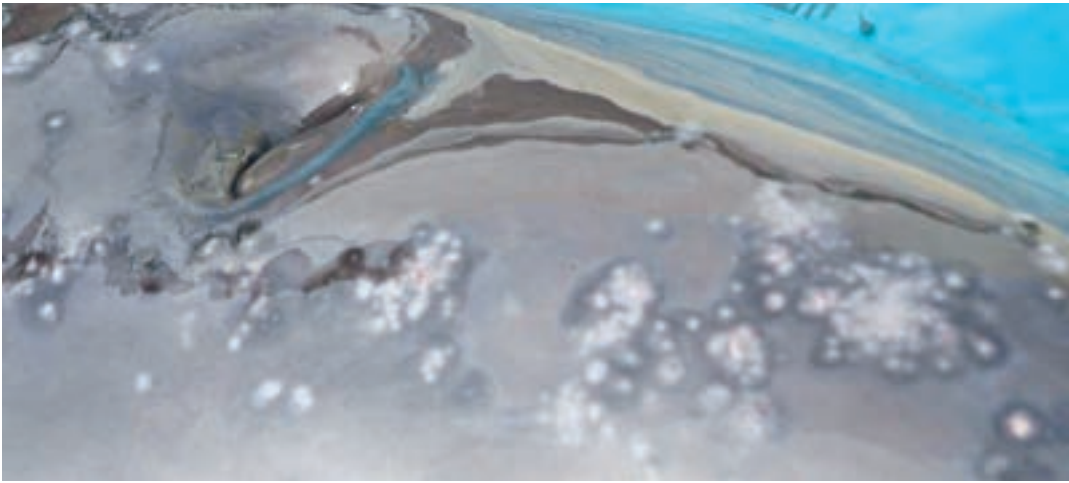


Figure 1. A rough-toothed dolphin (*Steno bredanensis*) who developed a secondary *Staphylococcus* infection after sustaining many mosquito bites on the melon and dorsum. The animal was treated with oral antibiotics, oral diphenhydramine, and topical zinc oxide, and lesions resolved. Photo courtesy of Lydia Staggs.

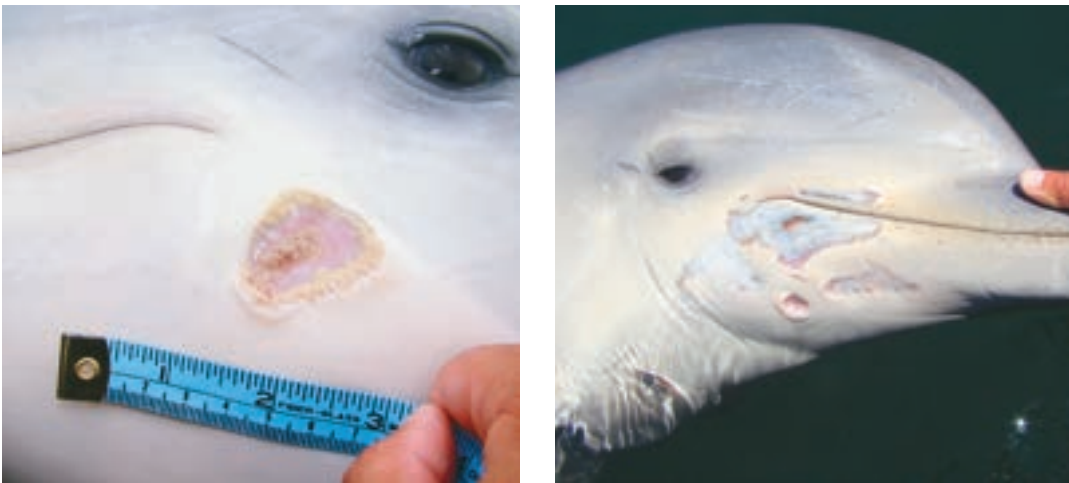


Figure 2. A young *Tursiops truncatus* upon initial presentation with *Staphylococcus ulcerative dermatitis* around the oral commissure (left and right). Biopsies of these lesions suggested a primary viral etiology and secondary *Staphylococcus* infection (*S. hominis* and *S. pasteurii*), however, no viral agent was identified. Photo courtesy of the Navy Marine Mammal Program.



Figure 3. The same juvenile *Tursiops truncatus* with *Staphylococcus superficial dermatitis* of the oral commissure after several months of topical therapy and a course of oral antimicrobials. Photo courtesy of the Navy Marine Mammal Program.

treatment while sensitivities are pending often includes oral amoxicillin/clavulanate, cephalosporins, fluoroquinolones, or tetracyclines. *S. aureus* is frequently pathogenic and should be treated based on sensitivity testing, as resistant bacteria continue to emerge.

Zoonotic Potential

Interspecies transmission was initially thought to be rare.¹³ Studies have demonstrated differences in the antimicrobial resistance patterns and subtypes

of *Staphylococcus* between managed dolphins and oceanarium personnel.⁶ More recently, however, Faires *et al.* demonstrated the ability of MRSA to colonize diverse animal species (dolphins and walrus) and provided evidence of transmission between humans and animals.¹³ Given the possibility of zoonotic and interspecies transmission, utilization of appropriate hygiene measures may be critical for management of Staph infections in animals, particularly when dealing with MRSA.¹³⁻¹⁴

REFERENCE

1. Bik, E. M. *et al.* Marine mammals harbor unique microbiotas shaped by and yet distinct from the sea. *Nature Communications* 7, 10516 (2016).
2. Jaing, C. *et al.* Pathogen surveillance in wild bottlenose dolphins *Tursiops truncatus*. *Diseases of Aquatic Organisms* 116, 83–91 (2015).
3. Monecke, S. *et al.* Diversity of *Staphylococcus aureus* Isolates in European Wildlife. *PLoS One* 11, (2016).
4. Morris, P. J. *et al.* Isolation of culturable microorganisms from free-ranging bottlenose dolphins (*Tursiops truncatus*) from the southeastern United States. *Veterinary Microbiology* 148, 440–447 (2011).
5. Schaefer, A. M., Goldstein, J. D., Reif, J. S., Fair, P. A. & Bossart, G. D. Antibiotic-Resistant Organisms Cultured from Atlantic Bottlenose Dolphins (*Tursiops truncatus*) Inhabiting Estuarine Waters of Charleston, SC and Indian River Lagoon, FL. *EcoHealth* 6, 33 (2009).
6. Streitfeld, M. M. & Chapman, C. G. *Staphylococcus aureus* infections of captive dolphins (*Tursiops truncatus*) and oceanarium personnel. *Am. J. Vet. Res.* 37, 303–305 (1976).
7. Venn-Watson, S., Smith, C. R. & Jensen, E. D. Primary bacterial pathogens in bottlenose dolphins *Tursiops truncatus*: needles in haystacks of commensal and environmental microbes. *Diseases of Aquatic Organisms* 79, 87–93 (2008).
8. Varaldo, P. E., Kilpper-Balz, R., Biavasco, F., Satta, G. & Schleifer, K. H. *Staphylococcus delphini* sp. nov., a Coagulase-Positive Species Isolated from Dolphins. *International Journal of Systematic Bacteriology* 38, 436–439 (1988).
9. Buck, J. D., Wells, R. S., Rhinehart, H. L. & Hansen, L. J. Aerobic microorganisms associated with free-ranging bottlenose dolphins in coastal Gulf of Mexico and Atlantic Ocean waters. *Journal of Wildlife Disease* 42, 536–544 (2006).
10. Mazzariol, S. *et al.* Death Associated to Methicillin Resistant *Staphylococcus aureus* ST8 Infection in Two Dolphins Maintained Under Human Care, Italy. *Front Immunol* 9, (2018).
11. Tamura, J. *et al.* Anesthetic management of an indo-pacific bottlenose dolphin (*tursiops aduncus*) requiring surgical debridement of a tail abscess. *Journal of Zoo and Wildlife Medicine* 48, 200–203 (2017).
12. Biberstein EL, Hirsh DC (1999) *Staphylococci*. In: Hirsh DW, Zee YC (eds) *Veterinary microbiology*. Blackwell Science, Ames, IA, p 115–119
13. Faires, M. C., Gehring, E., Mergl, J. & Weese, J. S. Methicillin-Resistant *Staphylococcus aureus* in Marine Mammals. *Emerg Infect Dis* 15, 2071–2072 (2009).
14. Gili, C., Biancani, B., Gulland, F. & Mazzariol, S. Methicillin-resistant *Staphylococcus aureus* (MRSA) associated dolphin mortality and the subsequent facility decolonisation protocol. *Veterinary Record Case Reports* 5, e000444 (2017).



Figure 4. Lateral body wall lesions on the same juvenile *Tursiops truncatus* as in Figures 2 and 3 with *Staphylococcus* superficial dermatitis. This animal had a hypo-pigmented sigmoid stripe (arrows) down the lateral body wall, with small, raised, vesicular lesions ranging in size from 1-7mm. These lesions waxed and waned over the course of a year. Photo courtesy of the U.S. Navy Marine Mammal Program



Figure 5. A rough toothed dolphin (*Steno bredanensis*), with ventral cervical *Staphylococcus* abscess (arrow), secondary to abrasions. The animal was treated with antibiotics and the abscess was flushed, which resolved the swelling. Photo courtesy of Lydia Staggs.




Figure 6. Young *Tursiops truncatus* with two deep *Staphylococcal* abscesses in the tail stock. Photo by Forrest Townsend

CHAPTER THREE: FUNGAL DISEASE

APOPHYSOMYCES ELEGANS COMPLEX

Lydia Staggs

Clinical Presentation

Apophysomyces elegans complex is composed of *Apophysomyces elegans*, *Apophysomyces ossiformis*, *Apophysomyces trapeziformis*, and *Apophysomyces variabilis*.² These fungi are responsible for the majority of Mucormycosis cases in Cetaceans. Mucormycosis is a fungal infection which has been historically rapid in onset, often resulting in acute death after clinical signs appear.⁶

A route of infection in healthy animals in good body condition is believed to be via inhalation of spores from surrounding contaminated soil. This results in colonization of the trachea and a systemic infection with tropism for brain tissue.^{1,6,7} Fungal invasion into peripheral blood vessels can cause infarction of the dermis supplied by the vessel resulting in a distinctive eschar lesion. In a retrospective study of managed care cetaceans, only 25% of the animals with the disease showed signs of skin lesions. Of the fatal cases of this disease, 100% of the animals had brain lesions caused by peracute brain hemorrhage.

Histopathology /Diagnostics

Histological review shows unique features including; broad, sparsely septate, thin-walled hyphae and angioinvasion with thrombosis.^{3,4,5,7}

Diagnosis can be achieved in two ways. These fungi are very difficult to culture, but can be done through a

biopsy or bronchial alveolar lavage. Authors recommend cultures not be frozen but sent on ice packs to Fungus Testing Laboratory at the University of Texas Health Science Center at San Antonio.

If there is no obvious lesion, serum can be collected and sent to Auburn University College of Veterinary Medicine for a Mucormycosis serology, which the authors have used successfully for diagnosis and management.

Treatment

Posaconazole is the treatment of choice for this disease. The standard dose recommendation is 5 mg/kg PO BID. After 2 weeks, it is recommended serum posaconazole levels be checked. At this time, a peak range of 2-5 ug/ml is considered therapeutic with the troughs going no lower than 1 ug/ml. Complete surgical excision of the skin lesion is strongly recommended.⁷

Zoonotic potential

Though humans have become infected from *A. elegans* complex, most often through traumatic injury, there are no reports of human infection from marine mammals.^{2,6}

Acknowledgments

This is a SeaWorld Parks and Entertainment technical contribution number 2018-20

REFERENCE

1. Kensel, M. 2003. Recently encountered central nervous system lesions in marine mammals: the importance of postmortem sampling of the CNS. Abstr., Proc. Annu. Int. Assoc. Aquat. Anim. Med. Waikaloa, HI, 34: 161-163.
2. Gomes, M. Z., Lewis, R. E., & Kontoyiannis, D. P. (2011). Mucormycosis caused by unusual mucormycetes, non-Rhizopus, -Mucor, and-Lichtheimia species. *Clinical Microbiology Reviews*, 24(2), 411-445.
3. Reiderson, T., McBain, J., Dalton, L., and Rinaldi, M.,. 1999. Diagnosis and treatment of fungal infections in marine mammals. In: Fowler, M. and Miller, R (eds.) *Zoo and Wild Animal Medicine*, 2nd ed. W.B. Saunders, Philadelphia, Pennsylvania. Pp. 478-485.
4. Reidarson, T., McBain, J., Dalton, L., and Rinaldi, M., . 2001. Mycotic Diseases. In: Dierauf L., Gulland F. (eds) *CRC Handbook of marine mammal medicine*, 2nd ed. CRC Press, Boca Raton, Florida. Pp 337-355.
5. Rinaldi, M., McGough, D., Fothergill, A., Walsh, M., Young, W., Dalton, L., McBain, J., Dickerson, S., Perry, C. and Stark, B.. 1989. Laboratory aspects of fungal infections and their therapy in marine animals. Abstr., Proc. Annu. Int. Assoc. Aquat. Anim. Med. San Antonio, TX, 20: 87-88.
6. Staggs, L., Townsend, F., Chesnut, E., Boston, J., Wells, R., Erwin, M., Petermann, E., Holmes-Douglas, S.. 2012. A Retrospective Study of Mucormycosis Cases in the Florida Panhandle From 1992–2012. Abstr., Proc. Annu. Int. Assoc. Aquat. Anim. Med. Atlanta, GA, 43
7. Robeck, T., Dalton, L. (2002) *Saksenaea vasiformis* and *Apophysomyces elegans*, Zygomycotic infections in Bottlenose Dolphins (*Tursiops truncatus*), a Killer Whale (*Orcinus orca*), and Pacific White-Sided Dolphins (*Lagenorhynchus obliquidens*)
8. Townsend, F., Williams, A. and Staggs, L.. 2006. The Successful Treatment of systemic zygomycosis in a bottlenose dolphin (*Tursiops truncatus*) calf. Abstr., Proc. Annu. Int. Assoc. Aquat. Anim. Med. Nassau, Bahamas, 37: 113-114

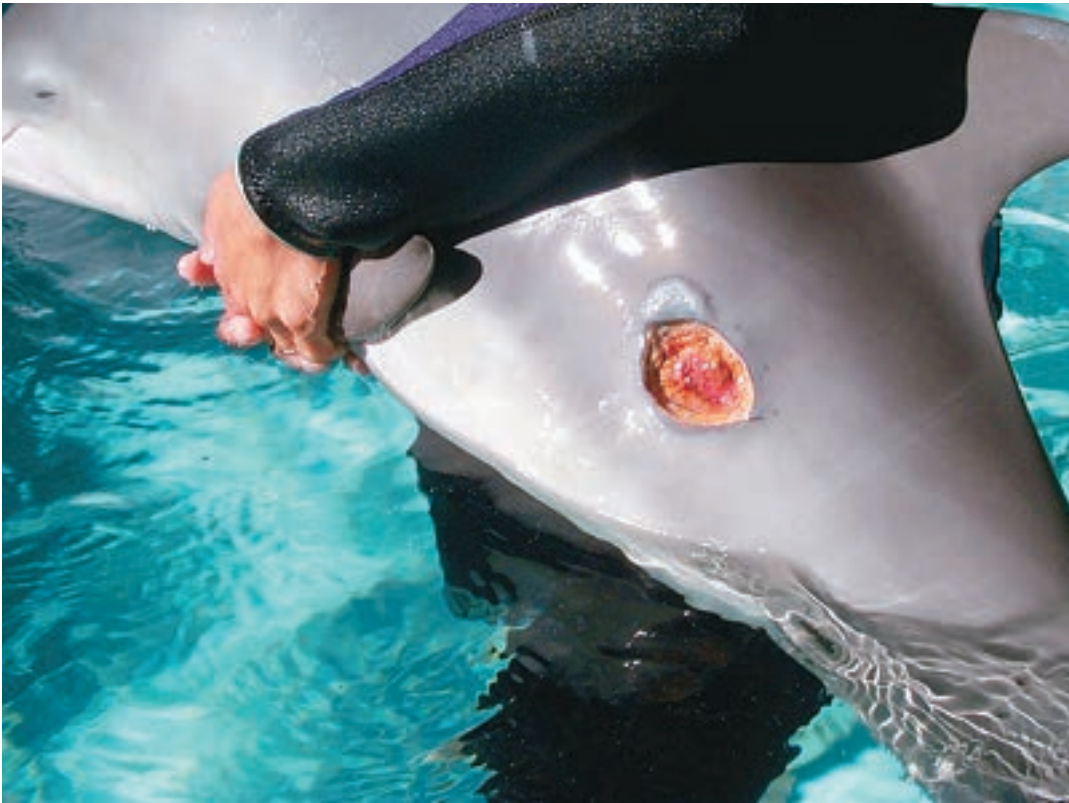

Figure 1. A five week old orphaned bottlenose dolphin calf infected with *A. elegans*. Note the regrowth forty-eight after surgical removal of the original infected area. Second surgical removal with the use of oral Posaconazole was successful in treatment. Photo by Forrest Townsend.



Figure 2. This photos shows the resection of a *Mucormycosis* skin lesion approximately ten days post-op in an adult bottlenose dolphin. Photo by Lydia Staggs.

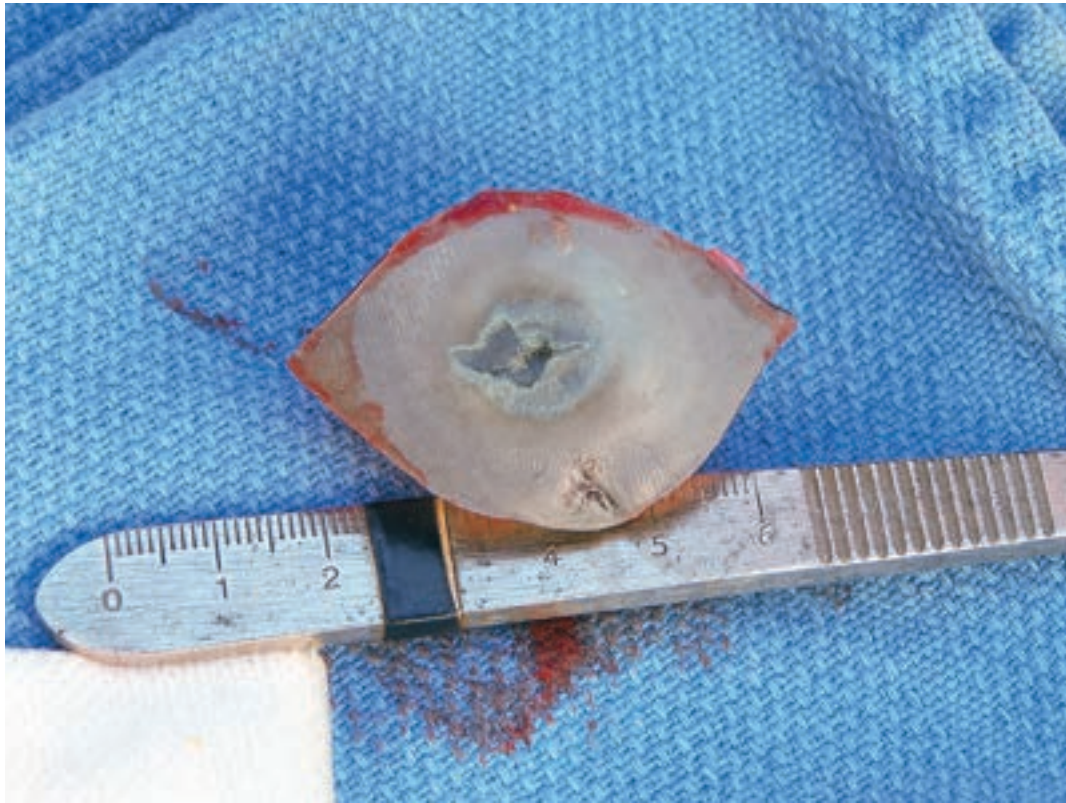


Figure 3. Gross lesion of *A. elegans* after surgical removal. Photo by Lydia Staggs.

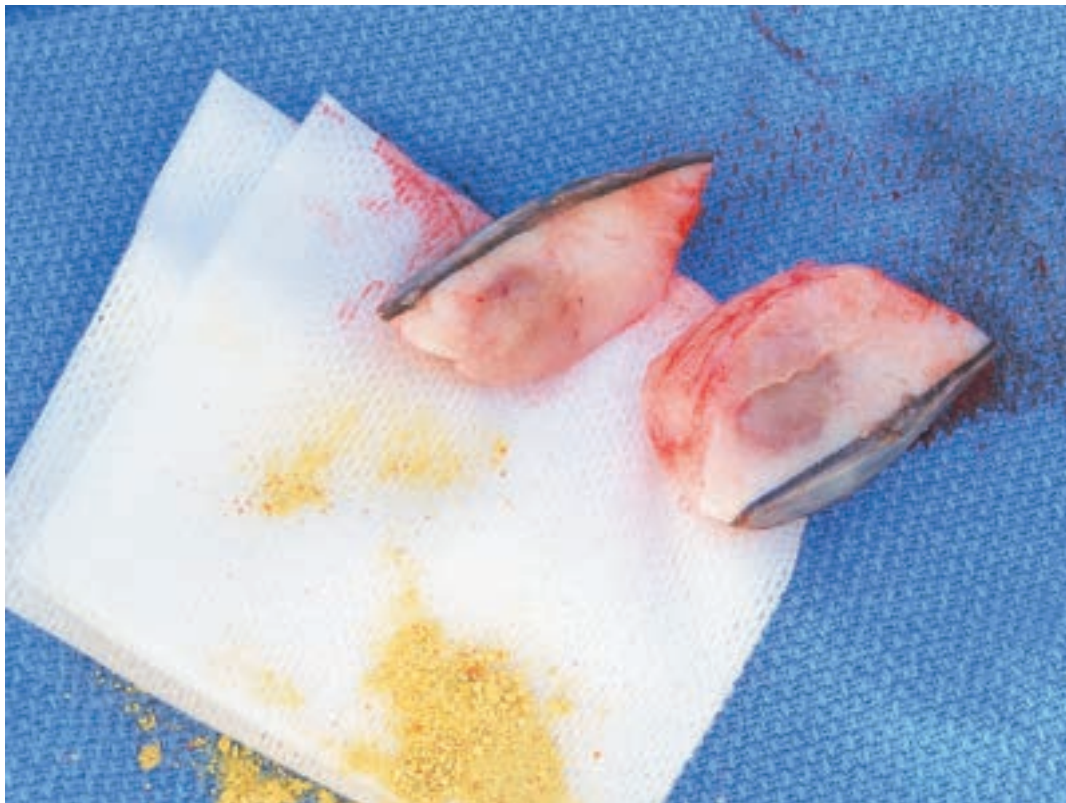


Figure 4

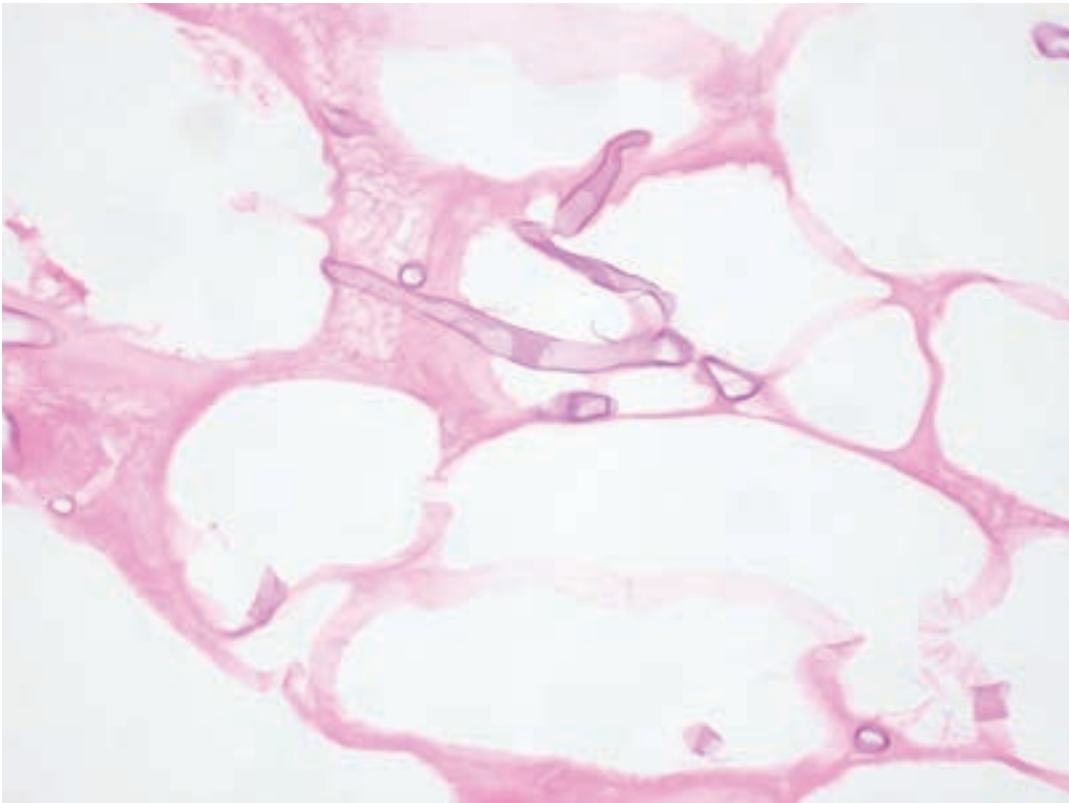


Figure 5. *H&E Stain of A. elegans found within the blubber sample from above. Photo by Diane Sips.*

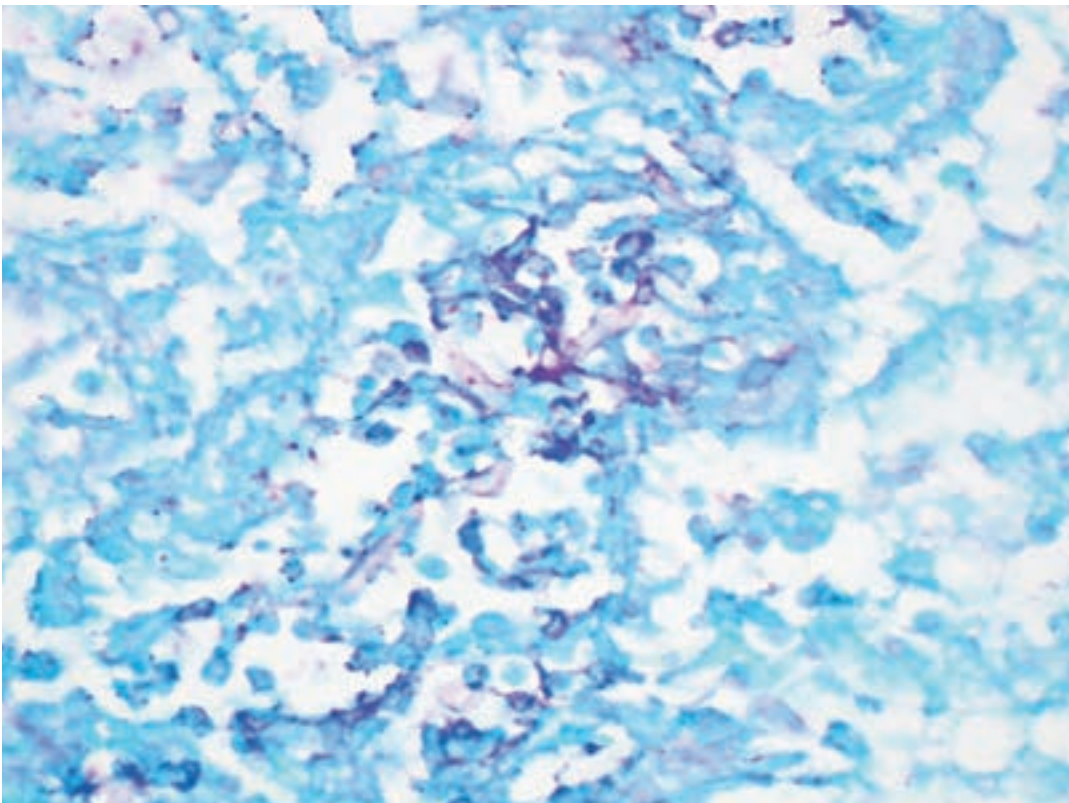


Figure 6. *PAS stain of A. elegans in the brain. Photo by Diane Sips.*

PARACOCCIDIOIDOMYCOSIS CETI (*Paracoccidioides brasiliensis* var. *ceti*)¹⁻² Formerly known as “LACAZIOSIS” OR “LOBOMYCOSIS”

Leslie B. Hart

Epidemiology

Paracoccidioidomycosis ceti, derived from an unculturable³ pathogen of the genus *Paracoccidioides*¹, has been detected in delphinid species since the 1970s in common bottlenose dolphins (*Tursiops truncatus*) and Guiana dolphins (*Sotalia guianensis*)⁴. In recent years, paracoccidioidomycosis ceti and paracoccidioidomycosis ceti-like* cases have been reported for four additional species:

- 1 Indo-Pacific bottlenose dolphin (*Tursiops aduncus*);
- 2 Australian snubfin dolphin (*Orcaella heinsohni*);
- 3 Indian Ocean humpback dolphin (*Sousa plumbea*)⁴;
- 4 Pacific white-sided dolphin (*Lagenorhynchus obliquidens*)⁵.

Cases of paracoccidioidomycosis ceti and paracoccidioidomycosis ceti-like* disease have been reported across the globe including coastal regions of the southeastern United States and Gulf of Mexico (Florida Keys, west coast of Florida, east coast of Florida, Texas, North Carolina)⁴, Mexico⁶, the Caribbean (Cuba), Central America (Belize, Costa Rica), South America (Brazil, Colombia, Ecuador, Peru, Venezuela, Suriname), western Europe (France), Madagascar and Mayotte, South Africa, Australia, and Japan⁴.

Clinical Presentation

Early presentation of this chronic, slowly-progressive, non-fatal disease includes verrucous lesions appearing as distinct raised fissures lighter in color than the surrounding tissue^{4,7}. In most reported cases, lesions are restricted to the skin and over time can form ulcerated keloidal plaques that are gray, white, pink or red in coloration^{4,7,8}, although a recent study observed infiltration into muscle tissue⁹. Lesions occur predominantly on appendages (i.e., pectoral fins, flukes) and dorsal body regions (i.e., dorsal fin, cranium/melon)⁴. The lesions do not appear to regress over time^{4,7}.

Histopathology

Microscopic examination using Gomori methenamine silver (GMS) stain reveals round and oval-shaped, thick-walled, uniformly sized (4-12 µm in diameter), yeast-

like organisms that form isthmus-connected chains^{2,8} resembling a ‘string of pearls’⁹.

Hematoxylin-eosin (H&E) stain reveals:

“Diffuse infiltrate containing macrophages, lymphocytes, plasma cells, fibrosis, and numerous yeast-like cells can be observed.”²

“presence of atrophy of epidermis with extensive fibrosis interspersed with microabscesses containing numerous lymphocytes, plasma cells, foamy histiocytes, and multinucleated giant cells”²

“acanthosis, hyperkeratosis, hyperpigmentation, and extensive progressive fibrosis are main features in dolphins”²

Currently, attempts to culture *P. ceti* have not been successful³.

Treatment/Prevention

Paracoccidioidomycosis ceti appears to be a chronic, non-fatal, slowly progressing disease. There is no current therapeutic treatment, and drug therapy attempts to resolve or reduce infection in captive dolphins have not been effective⁵. Lesions do not appear to regress in dolphins^{4,7}, and recurrence has been observed following surgical excision in human cases¹⁰.

Zoonotic Potential

Despite some similarities in microscopic and gross lesion appearance between dolphins and human cases of lacaziosis/lobomycosis and cross-reactivity with human *L. loboi* antigens², recent molecular analyses of *P. ceti* gene sequences have revealed closer homology to human strains of *P. brasiliensis* than *Lacazia loboi*^{1,5,8}. There is evidence to support that *L. loboi* and *P. ceti* may be two distinct species with a common genus ancestor (*Paracoccidioides*), rather than a single organism that is pathogenic to both dolphins and humans².

Dolphin to human transmission has been reported¹¹, but is considered rare. The zoonotic risk for *P. ceti* is considered low given the paucity of reported human infections following the handling of infected dolphins, as well as the absence of human infections in geographical areas with endemic dolphin disease (e.g.




Figure 1. *Silver stain of the lesion from above. Photo by Dianne Sips.*



Figure 2. *Photo by Roberto Sánchez.*

Indian River Lagoon, Florida)¹². Despite originating from two distinct pathogens (*L. loboi* and *P. ceti*), there

is some evidence that the marine environment may be a source of infection for both hosts¹³.

NOTE:

*Refers to probable cases of *P. ceti*, or “paracoccidioidomycosis ceti-like” disease (formerly “*Lacaziosis-like*” or “*Lobomycosis-like*”), which has a clinical presentation consistent with confirmed cases, but laboratory identification of the pathogen is unavailable.

REFERENCE

- Vilela, R., Bossart, G. D., Leger, J. A. S., Dalton, L. M., Reif, J. S., Schaefer, A. M., ... & Mendoza, L. (2016). Cutaneous granulomas in dolphins caused by novel uncultivated *Paracoccidioides brasiliensis*. *Emerging Infectious Diseases*, 22(12), 2063.
- Vilela, R., & Mendoza, L. (2018). *Paracoccidioidomycosis ceti (lacaziosis/lobomycosis) in dolphins*. In *Emerging and Epizootic Fungal Infections in Animals* (pp. 177-196). Springer, Cham.
- Schaefer, A. M., Reif, J. S., Guzmán, E. A., Bossart, G. D., Ottuso, P., Snyder, J., ... & McCarthy, P. J. (2016). Toward the identification, characterization and experimental culture of *Lacazia loboi* from Atlantic bottlenose dolphin (*Tursiops truncatus*). *Sabouraudia*, 54(6), 659-665.
- Van Bresseem, M. F., Simões-Lopes, P. C., Félix, F., Kiszka, J. J., Daura-Jorge, F. G., Avila, I. C., ... & Ott, P. H. (2015). Epidemiology of lobomycosis-like disease in bottlenose dolphins *Tursiops* spp. from South America and southern Africa. *Diseases of Aquatic Organisms*, 117(1), 59-75.
- Minakawa, T., Ueda, K., Tanaka, M., Tanaka, N., Kuwamura, M., Izawa, T., ... & Wada, S. (2016). Detection of multiple budding yeast cells and a partial sequence of 43-kDa glycoprotein coding gene of *Paracoccidioides brasiliensis* from a case of lacaziosis in a female Pacific white-sided dolphin (*Lagenorhynchus obliquidens*). *Mycopathologia*, 181(7-8), 523-529.
- Ramos, E. A., Castelblanco-Martínez, D. N., Garcia, J., Arias, J. R., Foley, J. R., Audley, K., ... & Van Bresseem, M. F. (2018). Lobomycosis-like disease in common bottlenose dolphins *Tursiops truncatus* from Belize and Mexico: bridging the gap between the Americas. *Diseases of Aquatic Organisms*, 128(1), 1-12.
- Burdett Hart, L., Wells, R. S., Adams, J. D., Rotstein, D. S., & Schwacke, L. H. (2010). Modeling lacaziosis lesion progression in common bottlenose dolphins *Tursiops truncatus* using long-term photographic records. *Diseases of Aquatic Organisms*, 90(2), 105-112.
- Rotstein, D. S., Burdett, L. G., McLellan, W., Schwacke, L., Rowles, T., Terio, K. A., ... & Pabst, A. (2009). Lobomycosis in offshore bottlenose dolphins (*Tursiops truncatus*), North Carolina. *Emerging Infectious Diseases*, 15(4), 588.
- Sacristán, C., Réssio, R. A., Castilho, P., Fernandes, N. C. C. D. A., Costa-Silva, S., Esperón, F., ... & Ott, P. H. (2016). Lacaziosis-like disease in *Tursiops truncatus* from Brazil: a histopathological and immunohistochemical approach. *Diseases of Aquatic Organisms*, 117(3), 229-235.
- Araújo, M. G., Cirilo, N. S., Santos, S., Aguilar, C. R., & Guedes, A. (2018). Lobomycosis: a therapeutic challenge. *Anais brasileiros de dermatologia*, 93(2), 279-281.
- Symmers, W. S. (1983). A possible case of Lobo's disease acquired in Europe from a bottle-nosed dolphin (*Tursiops truncatus*). *Bulletin de la Societe de Pathologie Exotique et de ses Filiales*, 76(5 Pt 2), 777-784.
- Reif, J. S., Schaefer, A. M., & Bossart, G. D. (2013). Lobomycosis: risk of zoonotic transmission from dolphins to humans. *Vector-Borne and Zoonotic Diseases*, 13(10), 689-693.
- Bermudez, L., Van Bresseem, M. F., Reyes-Jaimes, O., Sayegh, A. J., & Paniz-Mondolfi, A. E. (2009). Lobomycosis in man and lobomycosis-like disease in bottlenose dolphin, Venezuela. *Emerging Infectious Diseases*, 15(8), 1301.

CHAPTER FOUR: PROTOZOAN/ALGAE DISEASE

PROTOZOAN ULCERATIVE DERMATITIS

Bethany M. Doescher

The members of the *Kyaroikeidae* family of protozoa are commonly found in the respiratory tract of cetaceans. *Kyaroikeus cetarinus* are large, spindle-shaped ciliated protozoa, whereas the *Planilamina spp.* have an oval shape. Both have a round macronucleus.^{1,2} *Kyaroikeus* organisms have been found in the skin lesions of dolphins, but their pathogenicity at this site has not been documented.¹

In contrast, *Chilodonella sp.* is a pear-shaped ciliate that has two bands of cilia on their ventral surface. The anterior one-third of the cell is narrower and the cytoplasm is homogeneous, while the caudal two-thirds of the cell has a heterogeneous appearance with many inclusions. The macronucleus in the *Chilodonella* is an elongated oval. Light and transmission electron microscopy studies performed on *Chilodonella* isolated from skin lesions of dolphins have documented the presence of host cellular material within the protozoa, but no bacterial or fungal organisms. This suggests that the *Chilodonella sp.* are selectively feeding on the host tissue.^{3,4}

Clinical Presentation

Skin lesions associated with *Chilodonella sp.* can present in two ways, as a proliferation of pink to red friable tissue extending above the surface of the skin (*Figure 1a and 1b*) or as a moderate proliferation of tissue associated with progressive erosion of the host tissue (*Figure 2a and 2b*). Lesions may be found on the body or on the fins, especially along the trailing edge. *Chilodonella* are believed to be an opportunistic invader of pre-existing wounds, however, once present, they cause additional pathology. They have been isolated

from the wounds on *Tursiops* who are otherwise healthy and are often found in multiple sites on an individual, as well as on multiple animals within a group.⁴

Histopathology /Diagnostics

All of the protozoan spp. may easily be seen on a wet mount slide. The sample should include a small piece of the friable tissue from the margins of the wound which may be obtained by doing a routine skin scrape. The protozoa are more difficult to appreciate if the sample becomes desiccated, so the addition of a drop of saline to the sample at the time of collection will preserve sample integrity. The sample should be reviewed shortly after acquisition.

Chilodonella may be seen moving freely within the saline, but are more often observed at the margins of the tissue. You may also see individuals or clusters moving within the deeper layers of the tissue just below the surface. The organisms are usually clear, but may have a red hue consistent with consumption of the host tissue. Organisms may be seen using Diff-quick stain (*Figure 3a and 3b*). Diagnosis may be made based on the morphologic differences between the species with the most striking differences being the shape and the caudal placement of the internal structures.

Treatment

Topical application of hydrogen peroxide that is allowed to sit for 1-2 minutes up to three times per day has been successfully used to eradicate the protozoa from the wounds. A wet mount should be performed every other day and treatment continued until 3 consecutive samples are negative for the parasites. If the organisms have been found in multiple sites,

REFERENCE

1. Arkush, K.A., Van Bonn, W.G., Poynton, S.L. Identification of Ciliated Protozoans in the Respiratory Tract, Skin, and Somatic Lymph Nodes of Bottlenose Dolphins (*Tursiops truncatus*) from California, USA. IAAAM Conference Proceedings, 1998
2. Ma, H., Overstreet, R.M., Sniezek, J.H., Solangi, M. and Coats, D.W. (2006) Two New Species of Symbiotic Ciliates from the Respiratory Tract of Cetaceans with Establishment of the New Genus *Planilamina* n. gen. (Dysteriida, Kyaroikeidae). J. Eukaryot. Microbiol, 53(6), 2006 pp. 407-419
3. Poynton, S.L., Delannoy, M., Doescher, B.M., Renner, M., Clarke, A., Ma, H. Overstreet, R.M. Ciliates from Skin Lesions of Captive Bottlenose Dolphins (*Tursiops truncatus*). IAAAM Conference Proceedings 2008
4. Doescher, B.M., Renner, M. Clarke, A. Poynton, S. L. Ma, H. Overstreet, R.M. Cutaneous Ciliate Protozoan Infection in Healthy Atlantic Bottlenose Dolphins (*Tursiops truncatus*). IAAAM Conference Proceedings 2008

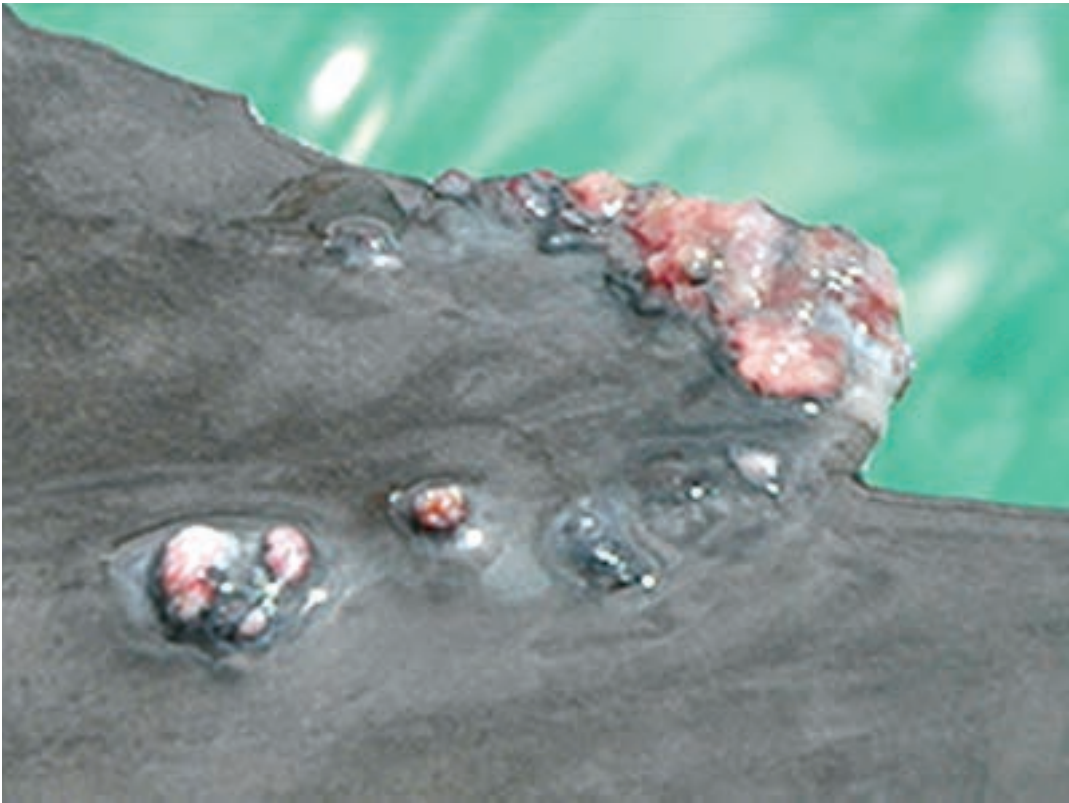


Figure 1A: Day 1- Nodular proliferation along the trailing edge of fin. Tissue is dark pink to red and very friable.

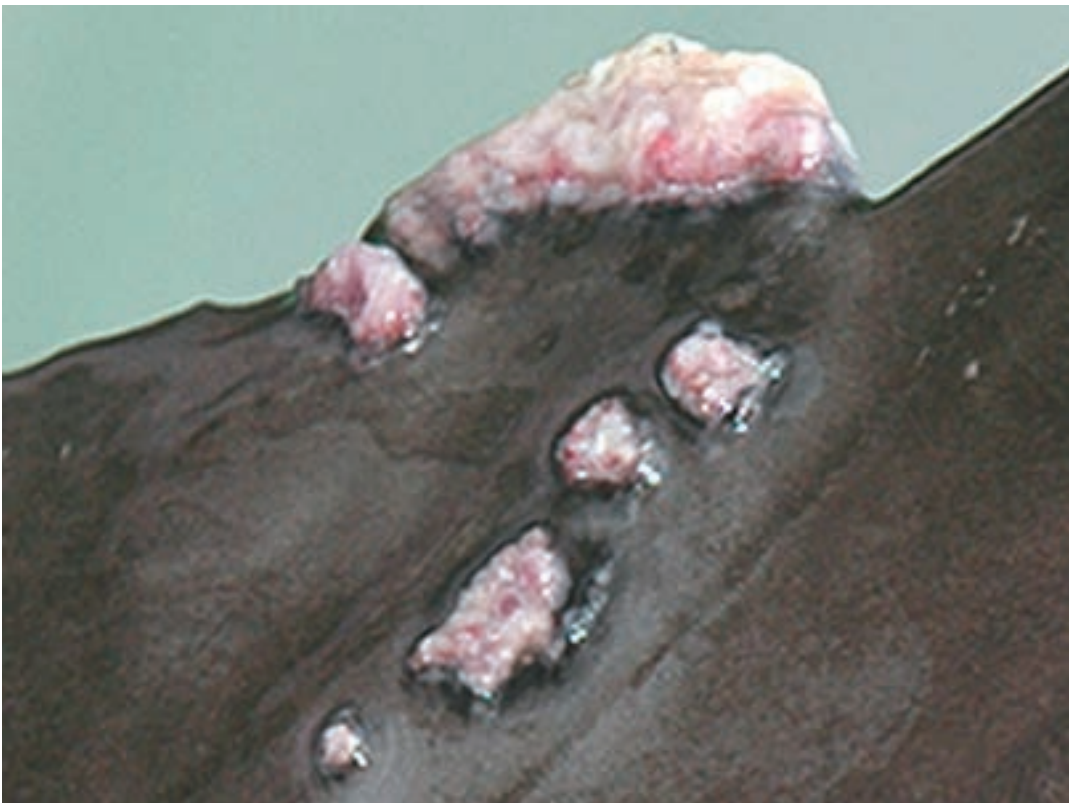

Figure 1B: Day 3- Lesions have coalesced and increased in size. Tissue now has an erosive appearance.

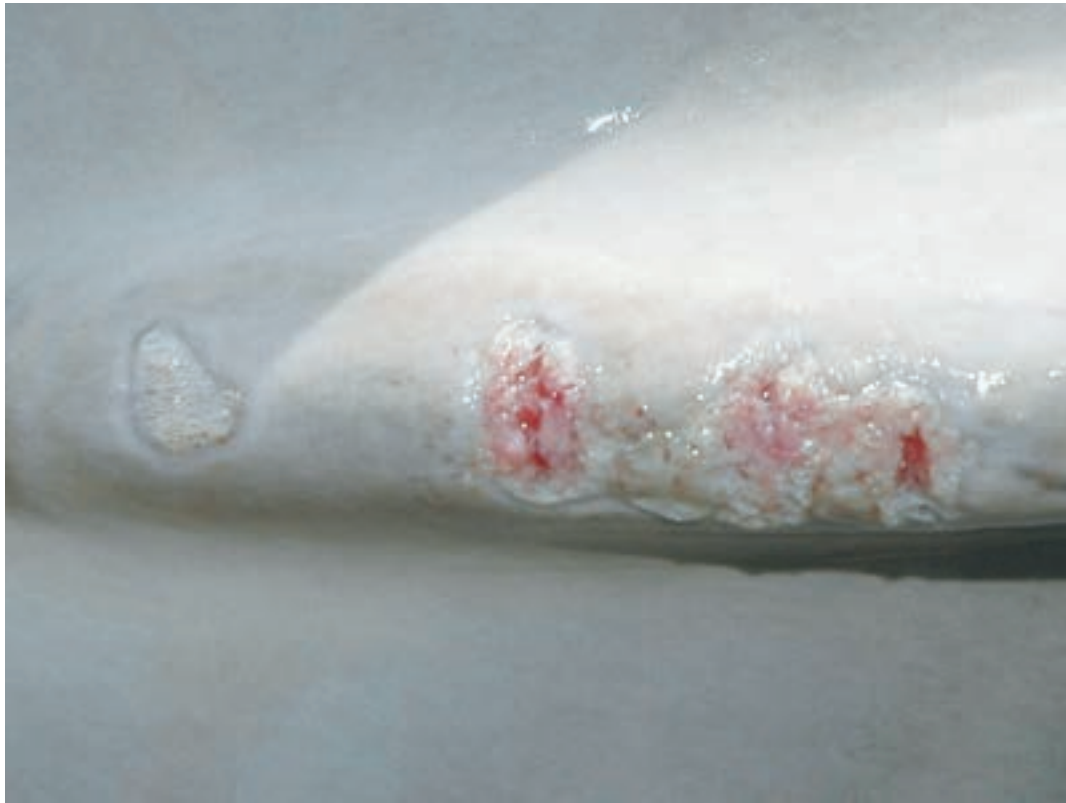

Figure 2a: *Erosive presentation on dorsal surface of the peduncle near fluke insertion.*

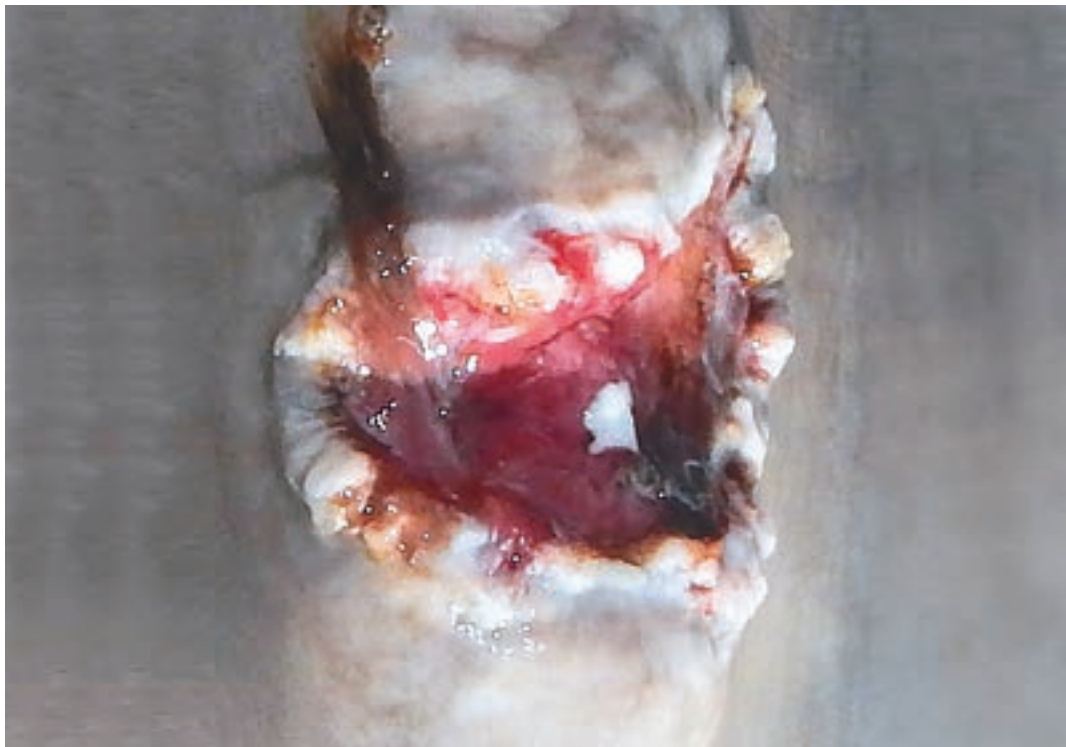

Figure 2b

representative samples from each site should be examined to confirm all sites are negative.

Zoonotic transmission to humans has not been documented..

Zoonotic potential

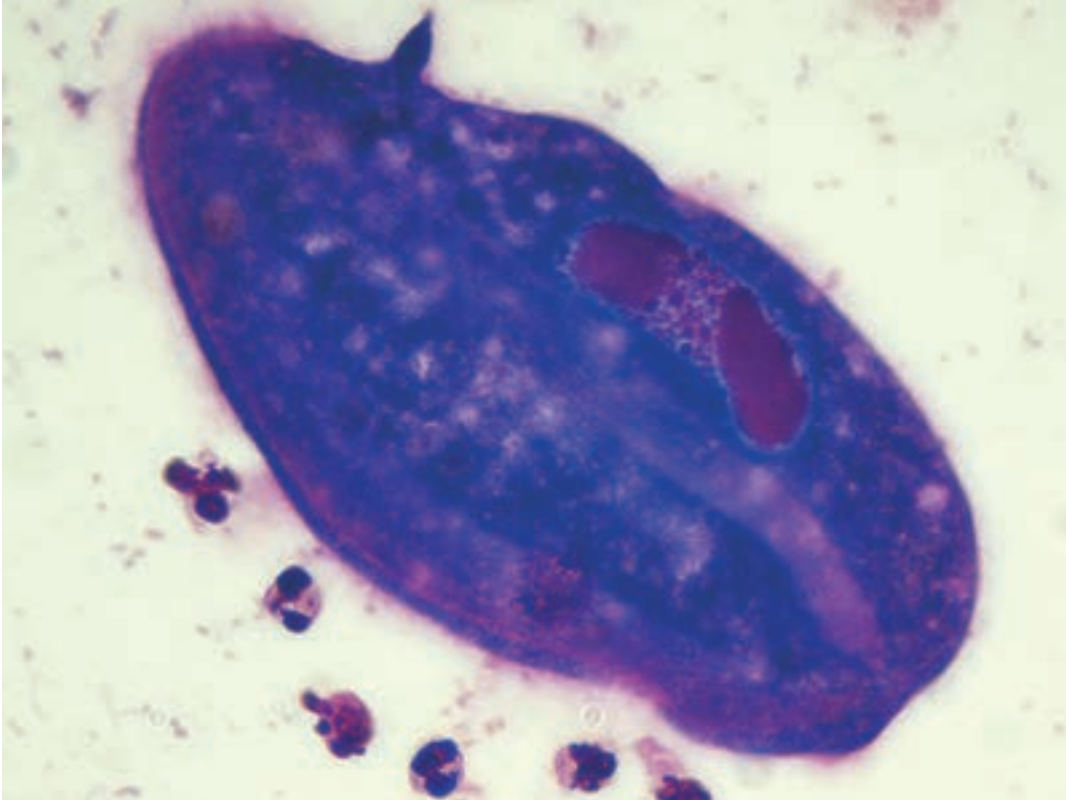


Figure 3A. Diff-quick Stain. a. A single *Chilodonella* organism (original magnification 1000x). Note the elongated oval macronucleus (**).

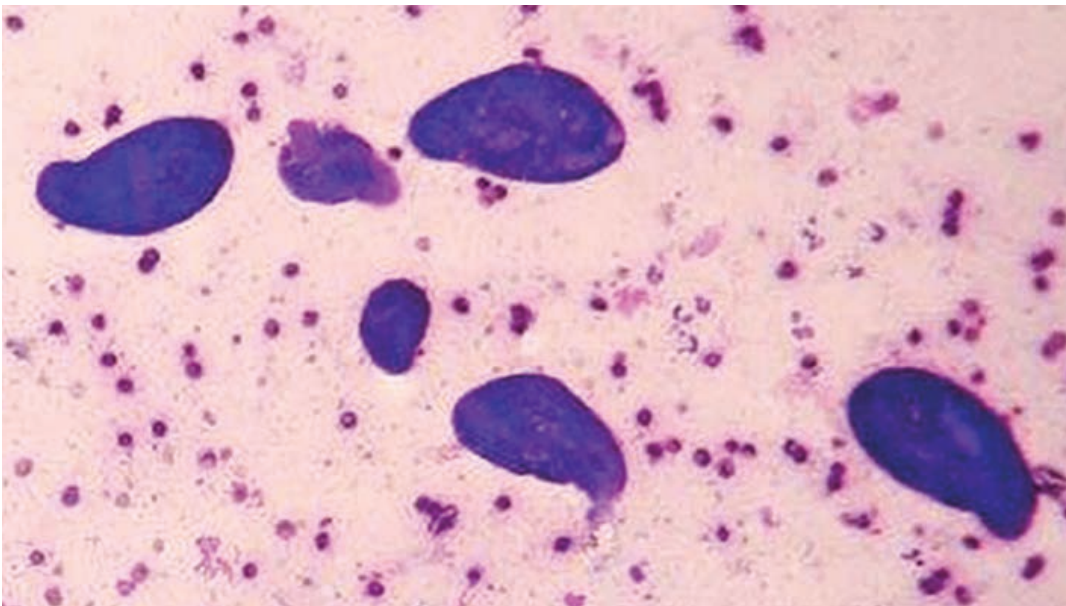


Figure 3B. Group of *Chilodonella* seen in a skin scraping (original magnification 400x).

CUTANEOUS DIATOMS

William Van Bonn

Clinical Presentation

Diatoms are a major group of aquatic unicellular microalgae. They are the dominant ecological producers in the ocean ecosystem. There is evidence that the evolution of cetaceans was enabled by the appearance and rise of diatoms. They are unique due to silica containing cell walls called frustules which are almost always bilaterally symmetrical, hence their common name. Although unicellular they frequently form colonies made up of massive numbers of individuals. These colonies may be grossly visible on the skin of cetaceans and have been described as skin films. As early as 1920 diatom films on whales were described and postulated to have been acquired by whales as they spent time in colder waters feeding. Fat whales almost always had skin films, thin whales did not.

Diatom species that have been described associated with cetacean skin films appear to be adapted to that habitat; they have not been found elsewhere. A new species of diatom was described from skin films seen on Atlantic bottlenose dolphins housed in San Diego bay.

Three free-ranging wild dolphin calves and one that presented as a stranded animal were reported to have yellow coloration of the skin. The authors of that report

postulated that diatom films, neonatal jaundice, or diet induced yellowing could have been the cause but no diagnostics were conducted.

Histopathology/Diagnostics

Diatom skin films typically appear as very thin patches of slight discoloration. They feel 'slimy' to the touch and are easily displaced from the skin. Sulphurous, yellowish, coffee colored, brown, greenish-brown, orange and 'buffish' are all terms that have been used to describe the appearance of these films. The early descriptions from large whales indicated the films often covered the entire surface of the animal. The cases observed in San Diego bay often involved patches along the dorsal and caudal aspects of the animals and were observed in the colder months of the year. Diagnosis is by microscopy of material collected from the film. Massive numbers of typical biraphid organisms dominate.

Treatment

None reported or presumed necessary. No pathology has been associated with diatom films.

Zoonotic Potential

None anticipated

REFERENCE

- Marx, F.G. and M.D. Uhen (2010): Climate, Critters, and Cetaceans: Cenozoic Drivers of the Evolution of Modern Whales. *Science* Vol 327, pp 993-996. DOI 10.1126/science.1185581
- Denys, L. & W. Van Bonn (2001): A second species in the epizoic diatom genus *Epipellicis*: *E. heptunei* sp. nov. – In: Jahn, R., J.P. Kociolek, A Witkowski & P. Compère (eds): *Lange-Bertalot-Festschrift*: 167-176. Ganter, Ruggell. - ISBN 3-904144-26-X.
- Feinholz, D.M. and S. Atkinson (2000): Possible aetiologies of yellow coloration in dolphin calves. *Aquatic Mammals*. 26.3 191-195.



Figure 1. A group of three dolphin with the predominant dolphin having a orange diatom lesion on its left side anterior and ventral to her dorsal fin. Photos courtesy of Chicago Zoological Society's Sarasota Dolphin Research Program taken under NMFS Permit #20455.



Figure 2. Photo by Chicago Zoological Society's Sarasota Dolphin Research Program NMFS Permit #15543.

CHAPTER FIVE: PARASITIC DISEASE

PENNELLA balaenopterae

Daniel Garcia

Pennella balaenopterae is a sessile parasitic copepod specific to marine mammals. Is the largest species in the genus *Penella*, the largest mesoparasite reported to infest cetaceans and bony fish with wide-ranging geographic distribution. Females can reach more than 30cm in total length. *P. balaenopterae* has been reported at least in 17 species of toothed and baleen whales^{1,2} and even described affecting pinnipeds³. Despite not being completely known, their indirect life cycle relies on teleost fish or cephalopod molluscs to become adults and mate. Inseminated females need to attach to cetaceans to complete the cycle⁴.

Clinical presentation

Individuals are most frequently observed over the flank and belly of the host, but can also affect the head and rostrum. The cephalothorax and anterior part of the thoracic region of *Pennella* are deeply embedded in blubber, even reaching muscle layers, being the rest of the parasite (neck, trunk, abdomen and ovisacs) clearly visible protruding from the skin surface like a filament. Free-swimming inseminated females infect cetaceans for feeding on blood and body fluids⁵. Typically only few individuals are infesting the host, but severe infestations are frequently observed. *P. balaenopterae* load has been postulated as a health status indicator in free-ranging cetaceans. Heavy parasite burdens have been linked with immunosuppression stages, primarily during viral epizootic events and/or substantial pollutants load.

Moreover, swimming behaviour alterations of the host associated to weakness or disease may promote *Pennella* infestations^{1,6}.

Histopathology / Diagnosis

Pennella copepods can be easily recognized at first sight without additional equipment. Main microscopic lesions on histopathology examination revealed moderate inflammatory response around the attachment site of the parasite, with lymphohistiocytic characters, eosinophils and microhaemorrhages infiltrating the dermis⁷. Other findings associated with the presence of parasite include necrotic lesions on blubber, bacteria presence, connective tissue infiltrated by neutrophils, mononuclear cell infiltration and signs of panniculitis⁸.

Treatment

Specimens are deeply attached to skin or muscle. Even careful copepod removal with forceps may leave parasite elements in the host tissue. While not reported in cetaceans, fresh water exposure could kill the copepod parasite as observed in other species. Due to the risk of secondary infection, topic and/or systemic antimicrobial treatment to control opportunistic bacteria may be recommended.

Zoonotic potential

Cetacean copepods are not reported as zoonotic to humans.

REFERENCE

- Vecchione, A., & Aznar, F. J. (2014). The mesoparasitic copepod *Pennella balaenopterae* and its significance as a visible indicator of health status in dolphins (Delphinidae): a review. *J. Mar. Anim. Ecol*, 7, 4-11.
- Fraija-Fernández, N., Hernández-Hortelano, A., Ahuir-Baraja, A. E., Raga, J. A., & Aznar, F. J. (2018). Taxonomic status and epidemiology of the mesoparasitic copepod *Pennella balaenoptera* in cetaceans from the western Mediterranean. *Diseases of aquatic organisms*, 128(3), 249-258.
- Dailey, M. D., Haulena, M., & Lawrence, J. (2002). First report of a parasitic copepod (*Pennella balaenopterae*) infestation in a pinniped. *Journal of Zoo and Wildlife Medicine*, 33(1), 62-65.
- Arroyo, N. L., Abaunza, P., & Preciado, I. (2002). The first naupliar stage of *Pennella balaenopterae* Koren and Danielssen, 1877 (Copepoda: Siphonostomatoida, Pennellidae). *Sarsia: North Atlantic Marine Science*, 87(5), 333-337.
- Raga JA, Fernandez M, Balbuena JA, Aznar FJ, (2009): Parasites. In: Perrin W, Wursig B, Thewissen JGM (eds.): *Encyclopedia of Marine Mammals*. Academic Press, San Diego, USA. 821-829
- Aznar, F. J., Perdiguero, D., Del Olmo, A. P., Repullés, A., Agustí, C., & Raga, J. A. (2005). Changes in epizootic crustacean infestations during cetacean die-offs: the mass mortality of Mediterranean striped dolphins *Stenella coeruleoalba* revisited. *Diseases of aquatic organisms*, 67(3), 239-247.
- Cornaglia, E., Rebora, L., Gili, C., & Di Guardo, G. (2000). Histopathological and immunohistochemical studies on cetaceans found stranded on the coast of Italy between 1990 and 1997. *Journal of Veterinary Medicine Series A*, 47(3), 129-142.
- Danyer, E., Tonay, A. M., Aytemiz, I., Dede, A., Yildirim, F., & Gurel, A. (2014). First report of infestation by a parasitic copepod (*Pennella balaenopterae*) in a harbour porpoise (*Phocoena phocoena*) from the Aegean Sea: a case report. *Vet Med*, 59(8), 403-7.



Photo credit Dr. Daniel Garcia, Fundación Oceanogràfic



Photo credit Dr. Daniel Garcia, Fundación Oceanogràfic

XENOBALANUS GLOBICIPITIS/ TASSEL BARNACLE PRESENCE

Lisa Quigley

Xenobalanus globicipitis, commonly referred to as the tassel barnacle or xeno, is a pseudo-stalked barnacle found on more than thirty-four species of cetaceans worldwide^{1,2}.

Clinical Presentation

Xenobalanus is most frequently observed along the trailing edges of the dorsal fin, pectoral fins, or flukes; however, on rare occasion xenos have been observed on the rostrum, teeth and along the body¹. Abundance varies greatly from a single barnacle to hundreds per individual host^{1,2,4,5}. Only a small portion of the barnacle, the base of the shell, is embedded into the outermost layer of the host's dermis and does not penetrate the blubber, leaving the majority of the flexible body extending from its mooring in the skin^{2,3}. The barnacle's body is long and thin, slimming near the shell. The body often appears dark red or black with a white, flower petal-shaped base (*Figures 1-2*). Xenos are commensal barnacles, relying on cetaceans primarily for transportation, feeding and refuge from predators. The cetacean host is typically unaffected by the barnacle; however, it may cause skin irritation or generate drag in the water¹. It is speculated that barnacle

presence may be an indicator of poor host health as they are commonly observed on unhealthy or stranded cetaceans^{3,5}. The etiology of barnacle presence, whether host-specific or environmental, is currently unknown^{1,2,5}.

Histopathology/ Diagnostics

Barnacle presence is easily recognizable by its protruding body extending from the host. On some occasion, the body is removed or lost and only the shell is left behind. This will appear as a small white stamp on the cetacean's body.

Treatment

There is no identified treatment known for xeno infestation. The body can be easily removed or scraped off being the body is not deeply embedded inside the host's skin. While never studied, exposure to fresh water may also cause the barnacle to die and fall off. Environmental parameters for xenos specifically have not been widely studied.

Zoonotic Potential

Barnacle occurrence is not zoonotic to humans.

REFERENCE

1. Bearzi M, Patonai K (2010). Occurrence of the barnacle (*Xenobalanus globicipitis*) on coastal and offshore common bottlenose dolphins (*Tursiops truncatus*) in Santa Monica Bay and adjacent areas, California. *Bulletin of Southern California Academy of Science* 109: 37–44.
2. Carrillo JM, Overstreet RM, Raga JA, Aznar FJ (2015). Living on the edge: settlement patterns by the symbiotic barnacle *Xenobalanus globicipitis* on small cetaceans. *PLoS ONE* 10(6): e0127367 doi: 10.1371/journal.pone.0127367.
3. Aznar FJ, Perdiguero D, Perez del Olmo A, Repulles A, Agusti C, Raga JA (2005). Changes in epizoic crustacean infestations during cetacean die-offs: the mass mortality of Mediterranean striped dolphins *Stenella coeruleoalba* revisited. *Diseases of Aquatic Organisms* 67: 239-247.
4. Toth-Brown J, Hohn AA (2007). Occurrence of the barnacle, *Xenobalanus globicipitis*, on coastal bottlenose dolphins (*Tursiops truncatus*) in New Jersey. *Crustaceana* 80: 1271-1279.
5. Scarano, LM (Unpublished). Investigating the attachment biology of the tassel barnacle, *Xenobalanus globicipitis*, and its incidence on dead and debilitated dolphins. College of Charleston, ProQuest Dissertations Publishing, 2016. 10133795



Figure 1.



Figure 2. *Single tassel barnacle attached to dolphin tissue.*

CHAPTER SIX: TRAUMATIC DISEASE

BIOPSY SCARS

Eric Zolman

Skin and blubber from free-ranging dolphins can be used for a wide range of analyses to provide insights into individual and population level health. Initially, these samples were used for sex identification (skin), stock structure delineations (skin), and persistent organic pollutant levels (blubber)^{1,2}. However, as analytical tools have advanced over the past 20 years, additional data can now be collected from skin and blubber including reproductive and stress hormones, stable isotopes, heavy metals, and a suite of emerging contaminants.

Skin and blubber samples from free-ranging dolphins are collected using two different methodologies: remote biopsy or wedge biopsy. Remote biopsy sampling uses a crossbow or modified rifle to propel a dart with cutterhead at a distance of 3 - 10 m, targeting the flank of the animal below the dorsal fin and above the midline³. Typical cutterhead dimensions for coastal and estuarine bottlenose dolphins in the southeastern U.S. are 8-10mm x 25mm and yield a remote biopsy that weighs ~0.7 - 0.8g). However, the size of the cutterhead and subsequent sample can vary by sampling season, geographic region, species, and/or project goals. Animal reactions are generally low, with a startle response immediately post-sampling. The remote biopsy location has been observed to have skin covering the wound at as early as 15 days post-sampling, and repigmentation of the biopsy location at ~60 days⁴. Once healed, the remote biopsy scar leaves a unique circular pattern that can be observed in photographic-identification images and/or during health assessments.

Wedge biopsies are collected while having “hands on” access during free-ranging dolphin health assessments. These biopsies are typically larger (30 X 50 mm maximum biopsy) than those collected via remote biopsy, however, as analyses continue to require smaller subsamples, the overall size of wedge biopsies have decreased over the past 20+ years. The wedge biopsy sampling location is usually 10 mm caudal and ventral to the following edge of the left side of the dorsal fin. After cleaning the skin with Chlorhexidine and isopropyl alcohol, a local anesthetic (2% lidocaine and epinephrine 1/100,000) is injected in a reverse “L” pattern to anesthetize the surgical site. Sterile technique is utilized to remove a blubber section down to the muscle fascial plane. When performed properly minimal hemorrhage is expected. The wound is packed with ferric subsulfate soaked gauze to help control any minor bleeding. If by chance the dolphin is part of another future health assessment, there is a minimum two year period prior to a second wedge biopsy, and if a second biopsy is taken, it is taken on the right side in the same area from the following edge of the dorsal fin. This dolphin # 826 was biopsied five days earlier and again with dolphin #826 at 47 days post biopsy revealing the healing of these type of wounds.

For both remote and wedge biopsies, the healed scars from these procedures can remain for many years post-sampling. During health assessments and strandings, it is useful to be observant of these scarring patterns as they are indicative that a given individual may have prior health data that could be applicable to the individual’s current health status.

REFERENCE

1. Kucklick, J., L. Schwacke, R. Wells, A. Hohn, A. Guichard, J. Yordy, L. Hansen, E. Zolman, R. Wilson, J. Litz, D. Nowacek, T. Rowles, R. Pugh, B. Balmer, C. Sinclair, and P. Rosel. 2011. Bottlenose dolphins as indicators of persistent organic pollutants in waters along the US East and Gulf of Mexico coasts. *Environmental Science and Technology* 45:4270-4277.
2. Rosel, P. E. 2003. PCR-based sex determination in Odontocete cetaceans. *Conservation Genetics* 4:647-649
3. Sinclair, C., J. Sinclair, E. Zolman, A. Martinez, B. Balmer, and K. Barry. 2015. Remote biopsy sampling field procedures for cetaceans used during the Natural Resource Damage Assessment of the MSC252 Deepwater Horizon oil spill, Pascagoula, MS. 36 pp.
4. Weller, D. W., V. G. Cockcroft, B. Würsig, S. K. Lynn, and D. Fertl. 1997. Behavioral responses of bottlenose dolphins to remote biopsy sampling and observations of surgical biopsy wound healing. *Aquatic Mammals* 23:49-58.



Figure 1. Permit number: No. 779-1633-00.
Photo credit: NOAA



Figure 2. Permit number: No. 779-1633-00.
Photo credit: NOAA



Figure 3. Permit number: No. 779-1633-00. Photo credit: NOAA

Figure 4. Permit number: No. 779-1633-00. Photo credit: NOAA

BOAT PROPELLER INJURY

Randall S. Wells

The relative importance of boat collisions as threats to marine mammals varies by species and habitat. Boats are among the most serious threats to manatees. Small cetaceans are struck by boat propellers much less frequently than are manatees, but collisions do occur nonetheless (Wells *et al.* 2008). Dolphins inhabiting shallow inshore waters are most often found with wounds believed to be from boat propellers. These dolphins, especially bottlenose dolphins, are exposed to increasing numbers of vessels as coastal human populations increase. In Sarasota Bay, Florida, a study found that resident bottlenose dolphins were exposed to a powerboat passing within 100m of each dolphin on average once every 6 minutes during daylight hours (Nowacek *et al.* 2001). When high speed passes by boats occur while dolphins are using shallow water habitats where they cannot dive beneath approaching boats, the probability of collisions increases. Such is believed to be the case for Sarasota Bay bottlenose dolphins during the summer, especially around the Independence Day holiday, when most collisions occur (Wells and Scott 1997). Resident bottlenose dolphins use shallow seagrass meadows more extensively in the summer, they are raising their naïve newborn calves in and near shallows, and spring/summer is the busiest boating season of the year – a dangerous combination.

Boat propeller wounds are typically characterized by multiple, evenly spaced, parallel cuts on the dorsal surface of the body from the spinning propeller blades, sometimes with a perpendicular wound running the length of the injury, from the propeller skeg

(Figures 1abc). Dolphins often survive shallow propeller injuries involving only soft tissue, including partial amputations of appendages (Wells *et al.* 2008). Given the soft nature of dolphin skin, little can be done to repair the tissue through intervention. Shallow, open wounds typically show granulation around the edges within several days, followed by scar formation. The distinctive scars can be used for photographic identification (Figures 1abc, 2; Wells 2018). In Sarasota Bay, about 5% of resident dolphins bear scars from boat strikes.

Deeper propeller wounds can be fatal, especially if they involve the skeleton. If the individual's mobility is compromised by the injury, secondary threats such as shark predation can become an issue. The two year old in figure 2 was struck by a boat propeller in April 2018 in rather deep wounds to the melon. The second photo was taken about one month later. This demonstrates the amazing healing abilities of these animal.

Propeller wounds can also lead to additional injuries and threats to a dolphin's survival. In some cases, fishing line has been seen trailing from propeller cuts. When algae gets caught in the line, it serves as a sea anchor, with the added drag creating additional cutting force on the line inside the propeller wounds, exacerbating the wounds and inhibiting the healing process.

REFERENCE

1. Nowacek, S. M., R. S. Wells and A.R. Solow. 2001. Short-term effects of boat traffic on bottlenose dolphins, (*Tursiops truncatus*), in Sarasota Bay, Florida. *Marine Mammal Science* 17:673-688.
2. Wells, R.S. 2018. Identification methods. Pp. 503-509 In: B. Würsig, J.G.M. Thewissen, and K. Kovacs, eds., *Encyclopedia of Marine Mammals*. 3rd Ed. Academic Press/Elsevier, San Diego, CA.
3. Wells, R.S. and M.D. Scott. 1997. Seasonal incidence of boat strikes on bottlenose dolphins near Sarasota, Florida. *Marine Mammal Science* 13:475-480.
4. Wells, R.S., J.B. Allen, S. Hofmann, K. Bassos-Hull, D.A. Fauquier, N.B. Barros, R.E. DeLynn, G. Sutton, V. Socha and M.D. Scott. 2008. Consequences of injuries on survival and reproduction of common bottlenose dolphins (*Tursiops truncatus*) along the west coast of Florida. *Marine Mammal Science* 24:774-794.



Figure 1a. 19 July 2012. *Chicago Zoological Society's Sarasota Dolphin Research Program taken under NMFS Permit #15543*



Figure 1b. 01 Aug 2012. *Chicago Zoological Society's Sarasota Dolphin Research Program taken under NMFS Permit #15543*



Figure 1c. 03 Sept 2017. *Chicago Zoological Society's Sarasota Dolphin Research Program taken under NMFS Permit #15543.*



Figure 2. *Chicago Zoological Society's Sarasota Dolphin Research Program, NMFS Scientific Research Permit No. 20455*

CIRCLE ENTANGLEMENTS

Forrest I. Townsend, Jr.

Clinical Presentation

It is not uncommon when observing wild dolphins, and whales for that matter, to see various materials (foreign objects) entangled around the animals. These materials come from a variety of human activities. Discarded fishing tackle with hooks, monofilament lines, leaders, lead weights and corks attached, heavier ropes and lines, commercial fishing gear including crab pot lines and buoys and other marine debris. The author has even heard once of a bikini bathing suit becoming entangled on a bottlenose dolphin.

Often the concern is when the entanglement is such that it can jeopardize the animal's health to the point that it may lead to its death. At this point a decision must be made to attempt to catch the entangled dolphin. This decision is not made lightly, not only is there a risk of injury or death to the targeted animal, there is also a human risk of injury as well. The logistics and expense involved with organizing a qualified capture crew is also a consideration.

An interesting scenario is a foreign body that encircles the body usually behind the blow hole and in front the dorsal fin.

A case in Barataria Bay, Louisiana a dolphin was first seen in 2010 with a light tackle wrapped around her body. From the appearance, it was thought this entanglement would resolve without human intervention. During a health assessment in 2017 this animal was once again observed. There was a ring of white scar tissue caudal to the blowhole. A decision was made to capture this dolphin. Photography of the lesion revealed a small line of pink granulation tissue in

the center of the scar tissue. With evidence there was a foreign body imbedded around this dolphin neck, this individual was captured with three other dolphins.

The lesion was two centimeters deep with what appeared to be a small diameter monofilament with a single knot (*Figure 3*). The gear analysis indicated it was from recreational sport fishery, nearshore, heavy 60 lb. test monofilament leader with knot that indicates bottom fishery. In the seven years this line was entangled some of the line had thinned a great deal to what appeared to be approximately 20 lb. test. It is somewhat amazing this much damage could occur. (*Figure 3 and 4*).

Another scenario involved a dolphin in the Savannah River in Georgia. This dolphin had been observed for several weeks with a foreign body encircling its body, appearing as black material. The dolphin was captured and the offending material was removed (*Figure 6*). On close inspection it appears to be rubber inner tubing about a half inch in width (*Figure 7*). There had been a similar material removed from a dolphin in Indian River Lagoon, Florida (*Figure 8*). It was suggested that this material was cut from tire inner tubes and used by commercial crab fishermen to secure the doors on their crab traps.

Histopathology /Diagnostics

Bacterial and or fungal culture may be of interest.

Treatment

Remove the offending material, taking care to remove all of the foreign material

Zoonotic potential

Not applicable.

REFERENCE

Story of this dolphin "FBYV7" can be viewed at
<https://www.carmmha.org/entangled-bottlenose-dolphin-rescued-in-barataria-bay-recap/>
<https://www.carmmha.org/dolphin-disentangled-by-carmmha-researchers-spotted-with-healthy-calf/>



Figure 1: 2015 Photographed in the field. Permit number: NMFS Scientific Research Permit No. 779-1633-02. Photo credit: NOAA



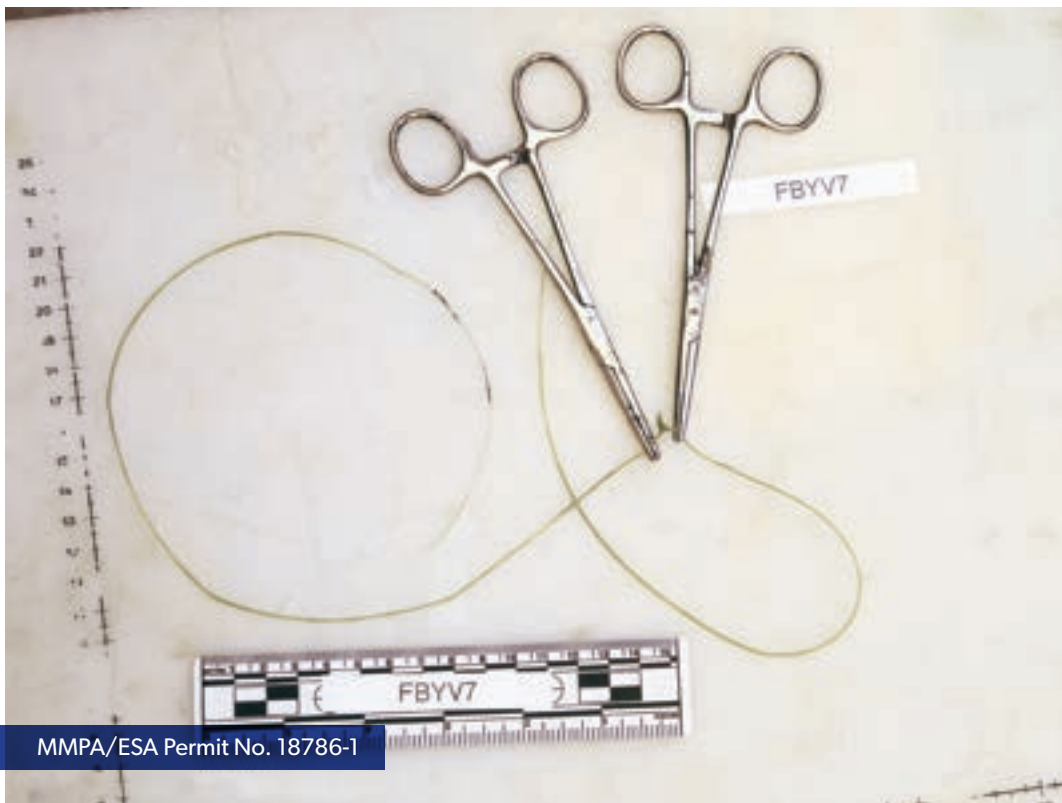
MMPA/ESA Permit No. 18786-1

Figure 2: Photo from September 2017 during removal of offending fishing line



MMPA/ESA Permit No. 18786-1

Figure 3



MMPA/ESA Permit No. 18786-1

Figure 4



Figure 5: *Dolphin Intervention / Savannah GA: July 1, 2008. Photo courtesy of GADNR.*



Figure 6



Figure 7



Figure 8: This rubber foreign body was from a similar circular entanglement case from the Indian River Lagoon in May of 2008.

COOKIECUTTER SHARK WOUNDS

Michael Scott

Cookiecutter sharks (typically *Isistius brasiliensis*, or possibly *I. plutodus*) are small predators/parasites/pests of marine mammals in warm oceanic waters. Described as a “melon baller with fins,”¹ this small shark apparently attracts larger and faster animals with its bioluminescence display, and then attaches to the skin of its target using suction applied by its modified lips and pharynx. The shark then twists and scoops out a disk of flesh with their razor-like lower teeth.^{1,2,3} During the day, these sharks swim at depths of 1000 m or more, but migrate vertically toward the surface at night.^{1,3}

Clinical Presentation

Cookiecutter sharks leave crescent-shaped cuts, or circular or oval craters about 2-10 cm in diameter.^{2,4} Because cookiecutter sharks may be schooling fish,¹ multiple wounds are possible.

Histopathology/Diagnostics

The shape and size of the crater-like wound is likely diagnostic of a cookiecutter shark bite. Healed wounds

are evident as circular, oval, or crescent-shaped scars. The scars may be depressed and permanent enough to allow photo-identification of individual marine mammals.⁵ The marine mammals most likely to be attacked are those living in tropical, pelagic waters, particularly near islands, where cookiecutter sharks are likely to occur. Most vulnerable are those species that are deep divers, and those that feed on vertically migrating prey at night, but even more-coastal dolphins have been attacked.⁶

Treatment

No treatment is typically required. In one documented case of a human victim, however, a 4-cm deep wound was debrided, subjected to negative pressure therapy, and closed with a skin graft.⁴

Zoonotic Potential

Not applicable



Figure 1: Cookiecutter shark (*Isistius brasiliensis*) Marine Vertebrate Collection, Scripps Institution of Oceanography

REFERENCE

1. Love, M.S. (2011). *Certainly More Than You Want to Know About the Fishes of The Pacific Coast: A Postmodern Experience*. Really Big Press, Santa Barbara, CA.
2. Jones, E.C. (1971). *Isistius brasiliensis*, a squaloid shark, the probable cause of crater wounds on fishes and cetaceans. *Fisheries Bulletin, U.S.* 69(4):791–798.
3. Compagno, L.J.V., Dando, M., Fowler, S. (2005). *Sharks of the World*. Princeton University Press, Princeton, NJ.
4. Honebrink, R., Buch, R., Galpin, P., Burgess, G.H. (2011). First documented attack on a live human by a cookiecutter shark (*Squaliformes, Dalatiidae: Isistius sp.*). *Pacific Science*. 65(3):365-374.
5. Wells, R.S. (2018). Identification methods. In *Encyclopedia of Marine Mammals*, 3rd edition (eds. B. Würsig, J.G.M. Thewissen, K.M Kovacs). Academic Press, San Diego, CA.
6. Grace, M.A., Aichinger Dias, L., Maze-Foley, K., Sinclair, C., Mullin, K.D., Garrison, L., Noble, L. 2018. Cookiecutter shark bite wound on cetaceans of the Gulf of Mexico. *Aquatic Mammals* 44(5):491-499.




Figure 2: *Pygmy Killer Whale*. *P*
hoto by Forrest Townsend.



Figure 3: *Goose Beaked Whale*.
Photo by Forrest Townsend.



Figure 4: *Off shore Tursiops truncatus* with fresh
cookiecutter bite wound. Photo Credit: NOAA South-
east Fisheries Service center Pascagoula, Mississippi.



Figure 5: *Off shore Tursiops truncatus* with healed
cookiecutter shark wound. Photo Credit: NOAA
Southeast Fisheries Service center Pascagoula,
Mississippi.

DORSAL FIN TAG ATTACHMENT IDENTIFICATION

Brian Balmer

The unique marks and scarring patterns on the dorsal fin of cetaceans is a common technique for identification of individual animals¹. These distinctive characteristics are derived from a variety of sources including inter- and intra-specific interactions as well as human-induced impacts such as fisheries entanglements and vessel strikes. The duration of these markings and scars can range from short-term (i.e. days to months), to long-term (i.e. across an animal's life) depending on the severity of a given interaction. During cetacean health assessments¹ and rehabilitation cases², prior to release, it is common for an individual animal to receive a tag attached to the dorsal fin. The type of tag is dependent on the researchers' goals. Rototags (*Figs. 1B and 2A*) are for short-term, visual identification, and are typically used to mitigate the risk of an animal being recaptured during a health assessment, or to assist researchers and/or the public in observing a rehabilitated animal post-release. Radio and satellite transmitters (*Figs. 1A and 2B*) are used to collect fine-scale data on movement patterns of an individual animal for up to several months. As technology has advanced over the past 20+ years, the size of radio and satellite tags have been greatly reduced, resulting in the miniaturization of tag packages requiring multiple attachment pins (*Fig. 1A*) to that of a single pin attached along the trailing edge of the dorsal fin (*Fig. 2B*).

The most recent, single pin tag designs are typically attached at a distance of 20 – 40 mm from trailing edge to attachment hole³.

In general, tags remain attached to the dorsal fin for a short-term interval (i.e. days to months) before being lost. The type of tag and number of attachment pins can greatly influence the observed markings and/or scarring patterns on the dorsal fin attributed to tag attachment. For larger tag packages with multiple attachment pins, these markings are evident (*Fig. 1*). However, for smaller tag packages with single pin attachments, these markings can be relatively subtle (*Fig. 2*). When a tag is lost, it either migrates through the dorsal fin leaving a characteristic clean, “U” (*Fig. 1B*) or “V” (*Fig. 2B*) notch, or it falls out at the point of attachment, leaving a circular hole. The well-healed, attachment hole may eventually fill in over time (*Fig. 2C*), leaving a slight scar, or can remain open for the rest of the animal's life (*Fig. 1C*). For all of the above scenarios, the evidence of the tag's attachment to the dorsal fin is an indicator that the animal may have additional health data from a previous time point. If the animal is handled during a future health assessment and/or stranding event, the unique markings caused by tag attachment may be the only tool, in the field, to identify if this animal had a previous health-exam history.

REFERENCE

1. Scott, M. D., Wells, R. S., Irvine, A. B., Mate, B. R. (1990) *Tagging and marking studies on small cetaceans*. In *The Bottlenose Dolphin*, Leatherwood, J. S.; Reeves, R. R., Eds. Academic Press: San Diego, CA; pp 489-514.
2. Moore, M., Early, G., Touhey, K., Barco, S., Gulland, F., and Wells, R. (2007) Rehabilitation and release of marine mammals in the United States: risks and benefits. *Marine Mammal Science* 23:731-750.
3. Balmer, B.C., Wells, R.S., Howle, L. E., Barleycorn, A. A., McLellan, W. A., Pabst, D. A., Rowles, T. K., Schwacke, L. H., Townsend, F. I., Westgate, A. J., Zolman, E. S. (2014) Advances in cetacean telemetry: a review of single-pin transmitter attachment techniques on small cetaceans. *Marine Mammal Science* 30:656-673.

FIGURE 1




Figure 1. Freezebrand animal 801 with (A) saddle pack including radio and satellite transmitters, 11 October 1999, (B) yellow rototag, 12 August 2003, and (C) no tags, 7 August 2006. Note for the saddle pack, the well-healed holes in the leading edge and “U” notches in the trailing edge, lower-third of the dorsal fin between A and B. Note for the rototag, the open hole in the trailing edge, middle-third of the dorsal fin between B and C.

NMFS Permit #: 779-1633-00 and General LoA #: 1064-1748.

FIGURE 2




Figure 2. Freezebrand animal Y79 with (A) yellow rototag, 13 June 2014, (B) satellite transmitter, 22 July 2016, and (C) no tags, 11 April 2017. Note for the rototag, the “V” notch in the trailing edge, upper-third of the dorsal fin between A and B. Note for the satellite tag, the well-healed hole in the trailing edge, lower-third of the dorsal fin between B and C. NMFS Permit #: 18786.

FISH NET MARKS ON CETACEANS

Sue Barco

Depending on the material from which they are made and the body part(s) with which they interact, net gear can leave many different types of marks on cetaceans.¹ Entanglement marks primarily occur on the rostrum, edges of the appendages (flippers, dorsal fin and fluke), dorsal and ventral keel of the caudal peduncle and/or around the head/thorax. It is uncommon for a net mark to occur only on a lateral surface (such as the thorax, neck, or on the flat surfaces of the flukes or flippers) without a corresponding mark on a leading and/or trailing edge.²

Net marks are characterized by multiple lesions that may either be spaced apart, sometimes on both the leading and trailing edge of an appendage (*Figure 1*) or may bunch either in the mouth, at the widest point of an appendage, at the insertion of an appendage, or on the body (*Figure 2*). The diameter of the twine (twine size), the amount of struggle by the animal, the drag on the gear, the length of time the gear was carried, and the shape of the affected body part(s) all dictate the width and depth of the mark(s) left on the animal.²

Nets made of monofilament tend to create lesions that are straight U-shaped furrows (*Figure 3*).^{1,2} Thinner monofilament will tend to cut into the epidermis while heavier, thicker twine may only leave an impression. Often the monofilament will cut into the leading edge of an appendage but only create an impression on the lateral surface. X- or V-shaped lesions are indications of net and are made when the corner of a square of mesh creates a lesion (*Figure 4*). Nets made from twisted (usually nylon) twine or other multifilament twine can leave marks that reflect the pattern of the individual strands that make up the twine.

Shallow net lesions may heal completely, abrasions and cuts into the dermis may leave a discolored scar or a disfigurement, and deep, chronic entanglement lesions may partially or fully amputate an appendage (*Figure 5*).

Marks can be made from buoy and anchor lines as well as net. Understanding what gear is used by local boaters and fishers is an important step in being able to identify entangling gear on cetaceans (*Figure 6*).



Figure 1: Net marks on the flipper of a bottlenose dolphin. The marks are indicative of a monofilament net with spaced cuts on the leading and trailing edge of the flipper and a linear impression on the flat surface (all images provided by Virginia Aquarium Foundation).

REFERENCE

1. Moore MJ, van der Hoop J, Barco SG, Costidis AM, Gulland FM, Jepson PD, Moore KT, Raverty S, McLellan WA (2013) Criteria and case definitions for serious injury and death of pinnipeds and cetaceans caused by anthropogenic trauma. *Diseases of Aquatic Organisms* 103: 229–264, doi:10.3354/dao02566
2. Moore KT & Barco SG (2013) *Handbook for Recognizing, Evaluating, and Documenting Human Interaction in Stranded Cetaceans and Pinnipeds*. U. S. Department of Commerce, NOAA Technical Memorandum, NOAA-TM-NMFSSWFSC-510, 103p



Figure 2: Net and gear can bunch up in a cetacean's mouth as seen here, or at other 'stopping points' on the animal's body such as flipper and fin insertion.



Figure 3: Monofilament net creates a straight U-shaped linear lesion as seen on the leading edge and ventral surface of a bottlenose dolphin flipper. Note that the lesion is deeper at the leading and trailing edges of the flipper and shallow along the flat surface.



Figure 4: Marks on the leading edge of a bottlenose dolphin flipper that are indicative of monofilament net with X- and V-shaped cuts from mesh..



Figure 5: Healed lesion on the leading edge of the left flipper of a stranded bottlenose dolphin most likely from a monofilament entanglement.

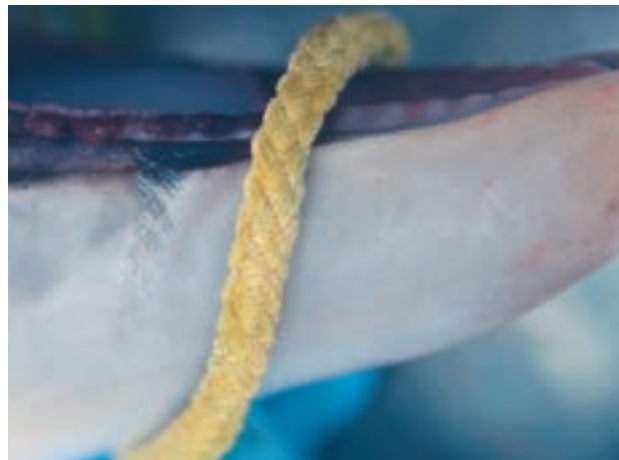

Figure 6: Comparing gear used in the region where the cetacean is found can help with identifying the source of marks. Here a line typically used as buoy lines for crab pot is compared with a lesion on the mandible of a young bottlenose dolphin.

FISH SPINE IN FLUKE AND TAIL STOCK (FISH WHACKING)

Jason B. Allen

Clinical Presentation

In the southeastern United States, bottlenose dolphins (*Tursiops truncatus*) perform a variety of specialized foraging behaviors including fish whacking¹. Dolphins will stun small fish by hitting them, sometimes high out of the water, with their fluke or peduncle. Fish with spiny dorsal, pelvic, anal, and or pectoral fins may puncture dolphin skin upon contact. The tips of these fin spines may break off and remain embedded in the dolphin.

Histopathology/Diagnostics

Punctures from fish fin spines in dolphin skin will present as small circular white lesions with a dark spot in the middle. They may be slightly raised and firm, especially when a piece of fish spine is embedded. Lesions will most likely appear on the dorsal or ventral surface of the fluke, or on the peduncle.

Treatment

Treatment should not be needed.

Zoonotic Potential

Not applicable.



The dolphin in the background has just whacked a mullet into the air while another (foreground) searches for more fish; Sarasota, FL.

REFERENCE

1. Wells, R.S., M.D. Scott, and A.B. Irvine. 1987. The social structure of free-ranging bottlenose dolphins. Pages 247-305 in H. Genoways (ed.). *Current Mammalogy, Vol. 1*. Plenum, New York, NY..



Lesions from fish spines on a dolphin peduncle during a health assessment in Sarasota, FL

FISHING LINE

Randall S. Wells

Recreational fishing gear is the most important anthropogenic threat to inshore dolphins in some areas of the southeastern United States. Entanglement in, ingestion of, or hooking by recreational fishing gear causes serious injury and mortality, and cases appear to be increasing with increased human use of coastal waters (Wells et al. 2008). As fishing line manufacturers work to make lines more effective for anglers, the decreased visibility of line in the water and increased strength and abrasiveness of some of the new products may be increasing the threat fishing line poses to small cetaceans (Barco et al. 2010).

This section considers only external entanglement in fishing line, not hooking or ingestion. Entanglements of small cetaceans in fishing line can take many forms, ranging from involvement of a single appendage (e.g., Figures 1,2) to multiple wraps of multiple appendages or body parts (Figures 3,4). Fishing line typically gets caught through the mouth (bridling, Figure 3), or on pectoral flippers (Figure 4), dorsal fins (Figures 3,4), or flukes (Figures 1,2). Multiple, constricting wraps of line around fin insertions can lead to amputation, blood loss, impaired mobility, and/or infection and death (Figure 4, Wells et al. 2008). Less severe injuries can lead to permanent scarring or mutilation (Wells et al. 1998). Scarring or mutilation can create individually distinctive, permanent features of utility for photographic identification (Figures 3,4, Wells 2018).

The severity of a wound and consequent scar vary with the nature of the entanglement, including such factors as:

- 1 the size and material of the line,
- 2 the number of wraps of line,
- 3 the quantity of line trailing behind the wound,
- 4 entanglement of other materials in the line,
- 5 duration of the entanglement, and the
- 6 location of the entanglement on the animal.

Wraps around one side of an appendage will typically create a notch (e.g., dorsal fin bases in Figures 3,4),

while wraps around appendages typically lead to cranial-caudal wounds, including V-shaped notches at each end (Figures 2,4). If wraps continue long enough, with constricting pressure on the line, then the cranial-caudal wounds may join, leading to amputation. Amputations may or may not be lethal, depending on the nature of the wound and its location. Amputation of distal ends of appendages typically is non-lethal, often leaving a fairly straight-line wound, reflecting the pull of the line as it cuts caudally through the appendage (Wells et al. 2008). Fishing line will collect algae, leading to increased drag and exacerbate line cutting through tissues (Figure 4).

Figure 1 shows the entanglement and mutilation of a fluke tip on a young male bottlenose dolphin (F222) in Sarasota Bay, Florida, before and after the line came off on its own. As of June 2018, the dolphin was still doing well, in spite of the fluke mutilation.

Figure 2 shows the fluke entanglement of an adult female dolphin (F113) in Sarasota Bay, Florida. This cranial-caudal wrap was constricting and probably would have led to an amputation had the line not been removed during a health assessment project in July 2012. The line had not been present during a May 2012 health assessment. As can be seen from a subsequent health assessment in June 2018, the cranial edge of the wound healed and filled in to some extent, leaving a notch, while a larger notch remained in the trailing edge of the fluke.

Figure 3 shows an entangled young male bottlenose dolphin, named “Vidalia,” near John’s Pass, Florida, in Fall 2011, exhibiting a bridling entanglement that extended under the right flipper and across the dorsal fin leading edge, with a large amount of trailing line and entangled debris. A rescue removed the line, but not before it left a notch at the base of the dorsal fin. The dolphin lived until May 2017, when it died from causes unrelated to the entanglement.

REFERENCE

1. Barco, S. G., L. R. D’Eri, B. L. Woodward, J. P. Winn and D. S. Rotstein. 2010. Spectra® fishing twine entanglement of a bottlenose dolphin: A case study and experimental modeling. *Marine Pollution Bulletin* 60: 1477-1481.
2. Wells, R.S. 2018. Identification methods. Pp. 503-509 In: B. Würsig, J.G.M. Thewissen, and K. Kovacs, eds., *Encyclopedia of Marine Mammals*. 3rd Ed. Academic Press/Elsevier, San Diego, CA.
3. Wells, R.S., S. Hofmann and T.L. Moors. 1998. Entanglement and mortality of bottlenose dolphins (*Tursiops truncatus*) in recreational fishing gear in Florida. *Fish. Bull.* 96(3):647-650.
4. Wells, R. S., J. B. Allen, S. Hofmann, K. Bassos-Hull, D. A. Fauquier, N. B. Barros, R. E. Delynn, G. Sutton, V. Socha and M. D. Scott. 2008. Consequences of injuries on survival and reproduction of common bottlenose dolphins (*Tursiops truncatus*) along the west coast of Florida. *Marine Mammal Science* 24:774-794.

Figure 1. *F222* right fluke tip entanglement.



a. *Entangled right fluke tip, August 24, 2005.*



b. *Fluke tip following shedding of line, March 31, 2008.*

Figure 4 shows a young female bottlenose dolphin, named “TORO,” first documented with a dorsal fin entanglement in Tampa Bay, Florida in May 2003. Historical photo-ID records and scarring on the dorsal fin suggested that there had been additional dorsal fin entanglements during March-May 2003. The dolphin was found and rescued in Charlotte Harbor in March 2004. Fishing line was embedded in the dorsal fin, with algae attached. This line was removed easily in the field. However, the right pectoral flipper had deep

constricting wraps of fishing line, cutting to the bone, leading to infection and necrosis of the fin (Figure 4). The extent of this injury led to the dolphin being brought into rehabilitation at Mote Marine Laboratory for further treatment. It was released two months later, and subsequent observations indicated its survival through at least September 2006. The cut through the leading edge of the dorsal fin healed, leaving a distinctive V-shaped notch.

Figure 2. *F113 right fluke blade entanglement.*



a. *July 20, 2012 disentanglement.*



b. *Examined during June 12, 2018 health assessment.*

Figure 3. *Vidalia* entanglement, photos by Ann Weaver.



a. *October 21, 2011*




b. *November 3, 2011*



c. *December 17, 2011, post-rescue, disentanglement.*

Figure 4. Time series of images of entangled dolphin TORO, before, during, and after entanglement, rescue, rehabilitation, and release.



a. March 14, 2003



b. May 26, 2003 (photo by Florida Fish and Wildlife Conservation Commission)



c. February 28, 2004, with algae caught on fishing line, prior to disentanglement, rehabilitation.



d-1. Rescue, showing dorsal fin and pectoral flipper fishing line entanglements (algae removed from dorsal fin line to show line involvement)



d-2.



d-3.



e. September 26, 2006, 2.5 years post-release.

GUNSHOT WOUNDS

Forrest Gomez

Clinical Presentation

Although the take of marine mammals is illegal under the U.S. Marine Mammal Protection Act of 1972, there is rising concern regarding the apparent increase in harassment of small cetaceans.¹ In areas such as the Gulf of Mexico, there has been an alarming increase in reported incidents of illegal harassment and feeding, to include fatal gunshot wounds.¹ Gunshot trauma often occurs where human recreational and commercial activities intersect with wild dolphin habitats and may result in clustering of cases during inshore migration.^{1,2} Gunshot wounds can vary greatly in size, shape and distribution depending on the weapon used, the proximity to the animal, the angle of the shot, the length of time since original injury, the type and amount of ammunition used, and the degree of secondary infection and inflammation.^{2,3,4}

Diagnosis

Penetrating bullet wounds should be examined as entry or exit wounds. Entry wounds can be blackened or singed and often have an abrasion collar of smooth,


inverting tissue.⁵ Exit wounds are sometimes larger than entry wounds and are usually characterized by jagged, irregular everting tissue.^{5,6} Gunshot wounds are known to cause infection of cartilage which may lead to dorsal fin collapse.^{7,8} If enough time has passed, it can be difficult to identify gunshot wounds in small cetaceans due to their excellent healing abilities.⁵ Care should be given to localize bullets or bullet fragments. If a bullet or shot is found, it should be collected as potential evidence and the case carefully documented.^{5,6} If radiography is an option, images should be taken of the areas with any possible wounds, looking for radiopaque material imbedded in the soft tissue.^{4,6}

Treatment

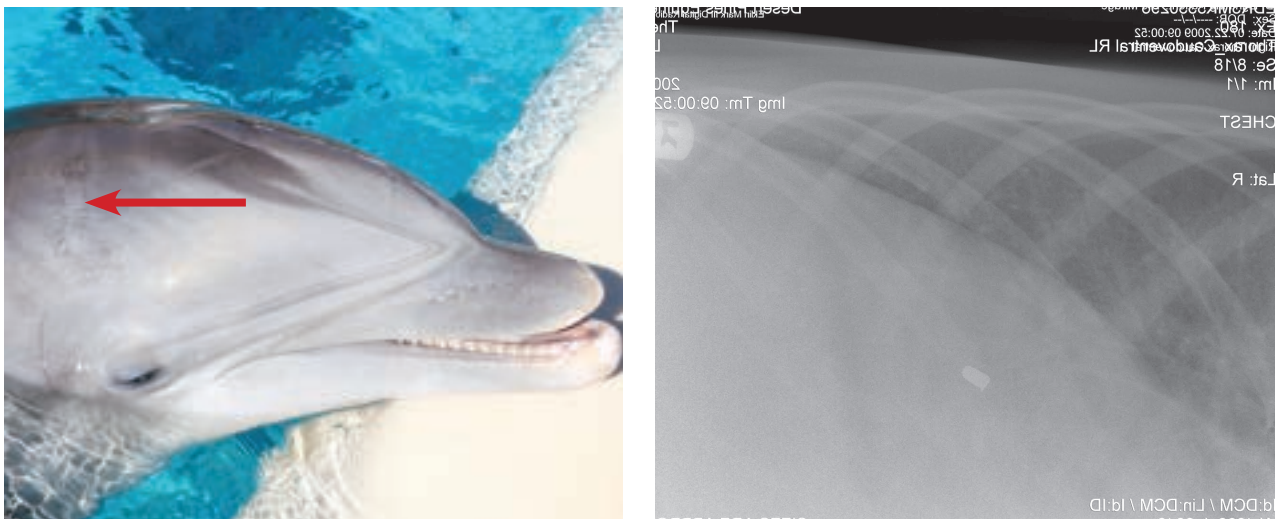
Potential treatment depends on the severity, chronicity, and location of the injury. Urgent and critical care should be provided when indicated. Surgical removal of the bullet material along with administration of systemic antibiotics, analgesia, and supportive care may be initiated if situationally appropriate.

REFERENCE

- Vail, C. S. 2016. An overview of increasing incidents of bottlenose dolphin harassment in the Gulf of Mexico and possible solutions. *Front Mar Sci* 3:110.
- Moore, M. J., van der Hoop, J. and S. G. Barco. 2013. Criteria and case definitions for serious injury and death of pinnipeds and cetaceans caused by anthropogenic trauma. *Dis Aquat Org* 103(3): 229-232.
- Fisher R. S. and C. S. Petty. 1977. Forensic pathology: a handbook for pathologists. *Department of Justice Doc No. O27-000-00541-1*, Washington, DC.
- Hare, M. P. and J. G. Mead. 1987. Handbook for determination of adverse human-marine mammal interactions from necropsies. *U.S. Department of Commerce, Northwest and Alaska Fisheries Service, Seattle*.
- Read, A. J. and K. T. Murray. 2000. Gross evidence of human-induced mortality in small cetaceans, US Department of Commerce, *NOAA Technical Memorandum, NMFS-OPR-15*.
- Moore, K. T. and S. G. Barco. 2013. Handbook for recognizing, evaluating, and documenting human interaction in stranded cetaceans and pinnipeds. *NOAA Technical Memorandum, NOAA-TM-NMFS-SWFSC-501*.
- Bigg, M. A., G. M. Ellis, J. K. B. Ford, and K. C. Balcomb. 1987. Killer whales: a study of their identification, genealogy, and natural history in British Columbia and Washington State. *Phantom Press, Nanaimo, British Columbia*.
- Hidgon, J. W. and D. Snow. 2008. First record of a collapsed dorsal fin in a white-beaked dolphin *Lagenorhynchus albirostris*, with a gunshot wound as a possible cause. *Canadian Field Naturalist* 122(3): 262-264.



Figures 1 & 2: Healed wounds and corresponding radiographs revealed metal pellets “bird shot”, in an adult female bottlenose dolphin. Photo credit Todd Speakman. Radiograph credit Dr. Jean Herman. MMPA/ESA Permit #: 18786-03.



Figures 3 & 4: Healed wound from gunshot with corresponding radiographs confirming a single bullet. Photo credit Stephanie Schmidt.

RAKE MARKS

Molly Martony

Clinical Presentation

Tooth scars or ‘rake marks’ are cutaneous lacerations inflicted through social interactions. These distinctive lesions occur as a result of natural conspecific exchanges driven by agonistic, sexual, or potentially play behaviors.¹ Lesions inflicted through interspecific exchanges between two different species or as a consequence of attempted predation have also been documented.^{2,3,4} Rake marks have been reported throughout odontocetes, including the Delphinidae, Physteridae, Platanistidae, and Ziphiidae families.⁵ Surveys of free-ranging populations have demonstrated frequent occurrences of rake marks, with 83.0% prevalence in Indian Ocean bottlenose dolphins, 29.1% in Atlantic spotted dolphins, and 49.3% in false killer whales.^{6,7} Evaluations of the distribution of rake marks among various age classes and sexes have provided biologist a glimpse into the complex social dynamics of odontocetes. Observations of cetaceans under managed care have demonstrated increased occurrence of the lesions on lower hierarchical or ill animals.

(F. Townsend, personal communication)

Gross distinguishing features include parallel, regularly spaced, straight to curved, transepidermal lacerations of variable length (*figure 1*). The width between individual lacerations corresponds to the distance between teeth of the inflicting species (*figure 2*). Typical lesions disrupt the epidermal-dermal layers and may extend into the blubber layer. Deeper tissues are usually spared facilitating re-pigmentation and resolve of most lesions over time.⁸ Lesion characteristics vary based upon the

stage of wound healing, with early lesions appearing as regions of broken skin, chronic lesions are comprised of scar tissue, and the final stages include dark-black coloration indicating re-pigmentation.⁷ Viral cutaneous lesions have occasionally been shown to emerge on regions of rake mark affected skin.⁹

Histopathology

Epidermal lacerations are characterized by dermal clefts that contain aggregates of degenerate inflammatory cells and fibrin which may extend into the dermas. Adjacent epidermis may have ballooning degeneration and disorganization of epithelial cells. The subjacent dermas often appears with congested blood vessels and infiltrates of inflammatory cells with degenerate neutrophils predominating.⁴ Later stages of wound healing are characterized by fibrosis and epithelialization.

Treatment

Topical wound care is typically indicated at most for the treatment of rake marks, due to the superficial nature of most lesions and the remarkable cutaneous healing capacity of cetaceans. Topical therapies may include antiseptics (chlorhexadine or povidone iodine), fresh water lavage, or antimicrobial preparations (neomycin bacitracin polymixin ointment or honey). On rare occasions extensive distributions of dermal lacerations and/or evidence of a systemic inflammatory response may warrant systemic antibiotics or consideration of anti-inflammatories.

REFERENCE

1. Marley M, Cheney B, Thompson P. Using tooth rakes to monitor population and sex differences in aggressive behavior in bottlenose dolphins (*Tursiops truncatus*). *Aquatic Mammals*. 2013;39(2):107-115.
2. George H, Philo J, Hazard K, Withrow D, Carroll G, Suydam R. Frequency of killer-whale (*Orcinus orca*) attacks and ship collisions based on scarring on bowhead whales (*Balaena mysticetus*) off the Bering-Chukchi-Beaufort Seas stock. *Arctic*. 1994;47:380-384.
3. Heithaus M. Predator-prey and competitive interactions between sharks and cetaceans: A review. *Journal of Zoological Society of London*. 2001;253:53-68.
4. Larrat S, Measures L, Lair S. Rake marks on a Harbor Porpoise (*Phocoena phocoena*) calf suggestive of a fatal interaction with an Atlantic white-sided dolphin (*Lagenorhynchus acutus*). *Aquatic Mammals*. 2012;38(1):86-91.
5. McCann C. Body scarring on cetacean-odontocetes. *Scientific Reports of the Whales of the Research Institute*. 1974;26:145-155.
6. Luksenburg J. Prevalence of external injuries in small cetaceans in Aruba waters, Southern Caribbean. 2014; PLOS ONE 9(2):e88988. Doi:10.1371/journal.pone.0088988
7. Scott E, Mann J, Watson-Capps J, Sargeant B, Connor R. Aggression in bottlenose dolphins: evidence for sexual coercion, male-male competition, and female tolerance through analysis of tooth-rake marks and behavior. *Behaviour*. 2005;142(1):21-44.
8. Lockyer C & Morris R. Some observations on wound healing and persistence of scars in tursiops truncatus. Individual recognition of cetaceans: Use of photo identification and other techniques to estimate population parameters. Report of the International Whaling Commission Special Issue 1990;12:113-118.
9. Smith A, Skilling D, Ridgway S. Calicivirus induced vesicular disease in cetaceans and probable interspecies transmission. *Journal of the American Veterinary Medical Association*. 1983;83:1223-1225.



MMPA/ESA Permit No. 779-1633-00

Figure 1. *Fresh rake marks identified on a free ranging bottlenose dolphin. Photo credit NOAA*



MMPA/ESA Permit No. 18786-03

Figure 2. *Healing rake marks on the fluke of a bottlenose dolphin.*

SHARK BITES

Krystan A. Wilkinson

Clinical Presentation

Sharks are natural predators of a variety of small cetacean species¹. Although the most common interaction documented between these taxa is shark predation on cetaceans, interactions between sharks and cetaceans can be complex. Some shark species may not be a predator of small cetaceans, yet they may scavenge on cetacean carcasses¹. For example, a live common bottlenose dolphin (*Tursiops truncatus*) stranded on the central Gulf coast of Florida with several fresh shark bite wounds (G. Lovewell, personal communication). Shortly after stranding, the animal expired on her own. Blacktip shark (*Carcharhinus limbatus*) teeth, an unlikely bottlenose dolphin predator, were recovered at the wound site during necropsy. Conversely, a few cetacean species have been documented to prey on small species of sharks¹ and some species within these taxa may also be considered competitors for food and habitat resources in localized ecosystems¹.

Risk of shark predation has long been suggested to be an important consideration shaping group living and habitat use in cetacean species²⁻⁴. Many studies have described shark predation on nearshore bottlenose dolphins (*Tursiops spp.*⁵⁻⁸); however, shark predation in a variety of other cetacean species has also been documented^{1,9}. Failed predation attempts leave distinctive wounds and scars on surviving cetaceans (Figures 1 and 2). These scars may remain visible over a dolphin's lifetime⁸. Shark bite wounds appear to naturally heal within a few weeks^{10,11}. Fresh shark bite wounds and evidence of scavenging can also be documented on stranded animals or recovered carcasses.

The distribution of shark bites on the body of cetaceans is non-random. In some study sites, more bites have been observed on the dorsal and lateral surface on living cetacean individuals than the ventral surface^{7,12}. However, this finding is not consistent among species and locations. As an example, no difference in the location of shark bites was observed on Atlantic spotted dolphins (*Stenella frontalis*) near Bimini, The Bahamas¹³. White sharks (*Carcharodon carcharias*) have been documented to target the peduncle and ventral areas of living cetaceans⁹.

Shark bites that occur on the head, ventral surface, or peduncle on living cetaceans may be more successful predation attempts⁷. Commonly shark scavenged areas of the cetacean body include the ventral and posterior surfaces⁶.

Shark bite occurrence frequency can vary widely among cetacean species and study sites. For example, on *Tursiops aduncus*, scarring frequency in Shark Bay, Australia has been documented to be as high as 77%⁷, compared with 36.6% in Moreton Bay, Australia⁵ and 16.9% in Bunbury, Australia¹⁴. Common bottlenose dolphins in Sarasota Bay, Florida have a shark bite scarring frequency of 35.5%⁸, a rate higher than that found on this species in Natal, South Africa (10%-19%)⁶. Assessment of shark bite scarring frequency in the Kimberley region of northwestern Australia revealed that the Australian snubfin dolphin (*Orcaella heinsohni*) had a higher shark bite frequency (72%) than the Australian humpback dolphin (*Sousa sahalensis*, 46%) or bottlenose dolphin (*T. aduncus*, 18%) found in the same region¹². Shark bite scarring frequency on *Stenella frontalis* in the Bahamas has been documented to be 15%¹³. Observed differences in shark bite scarring rates among species and sites may be a result of the probability of death during a shark encounter, as well as differences in cetacean and shark species and sizes found among the various locations⁷.

There are several species of sharks whose diets include cetaceans. While characteristics of shark bites vary among shark genera and species^{1,7}, determining the size and species of shark that inflicted the wound is difficult. Geographical distribution and feeding behavior can help to narrow the list of possible shark genera or species responsible for the wounds. Determining size and species can only be done with fresh wounds as wound healing may vary across individuals (i.e., scars may stretch as the cetacean grows). Size estimates of sharks based on bite morphometrics may be misleading due to several sources of error, such as lack of complete bite and overlapping multiple bites⁹. Despite these limitations, such measurements can be informative to suggest a general size class or life stage of the shark in question.




Figure 1. Female resident bottlenose dolphin (*Tursiops truncatus*) in Sarasota Bay, Florida with fresh shark bites. (a) A crescent-shaped shark bite, consistent with a shark jaw can be observed; (b) in addition to a crescent-shaped shark bite on the left side of the animal, deep, widely spaced lacerations are present. Photos were taken by the Chicago Zoological Society's Sarasota Dolphin Research Program under a series of NMFS scientific research permits, most recent #20455.




Figure 2. Examples of shark bite wound healing in bottlenose dolphins (*Tursiops truncatus*) near Sarasota Bay, Florida. (a) In May 2016 a recently born dolphin calf was documented with fresh shark bites near the right eye and on the dorsal fin, (b) by August 3, 2016 the wounds on the calf appear healed. (c) In September 2014, a female dolphin was documented with fresh shark bites on the left side of the body and the anterior portion of the dorsal fin, (d) by October 2014 the wounds appear to be healed. Photos were taken by the Chicago Zoological Society's Sarasota Dolphin Research Program under a series of NMFS scientific research permits, most recent #20455.

Histopathology/Diagnostics

Wounds are considered to be shark-inflicted if they are crescent-shaped, consistent with a shark jaw (*Figure 1*), or consist of deep, widely spaced lacerations that could not have been caused by another dolphin⁷ (*Figure 1*). These wounds may be accompanied by individual tooth punctures. Scalloping in some areas of the wound may also be present. Shark-inflicted wounds may be deep, causing abrasions on the bone.

Shark bite wounds are most commonly categorized as either occurring premortem or postmortem; however, perimortem bites may be identifiable in a select number of cases. The timing of shark bite wounds can be distinguished as follows:

Premortem: Bite wounds occurring on living individuals are classified as premortem. Living individuals may heal from a shark bite wound without human intervention (*Figure 2*). If a carcass is recovered with fresh shark bites, wounds can be determined as premortem if there is evidence of tissue response at the wound site, which may include granulated tissue formation, congestion, hemorrhaging, and hematoma (bruising) along the blubber-muscle interface (*Figure 3*);

Perimortem: These occur at or near the time of death. For example, the cetacean may be compromised and while in the process of stranding or dying, it may attract the attention of nearby sharks and receive a shark bite. At present, this classification is not commonly distinguished from premortem bites and may only be differentiated as perimortem with eyewitness observation of the shark-cetacean interaction;

Postmortem: Scavenging by sharks on cetacean carcasses is not uncommon; thus, postmortem bites on recovered carcasses may be present. While bites occurring postmortem may discharge blood, bites can be determined as postmortem if there is an overall lack of tissue response at the wound site (*Figure 4*).

In many cases, determination of open wounds as premortem versus postmortem can only be done with relatively fresh carcasses. However, open shark bite wounds on cetacean carcasses can also be confirmed as premortem or postmortem bites with histological

analysis of the tissue at the wound site. Recovered carcasses may also have both pre- and postmortem bites present.

Currently, there is no consensus in the literature regarding which measurements of fresh shark bite wounds to take on recovered cetacean carcasses. Tooth shape, size, and spacing vary among genera and species of shark⁹. Measurements that may be helpful in identifying the size and species of the shark include:

If bite wound is crescent-shaped:

1. bite width, or diameter^{6,7,9}
2. height, or reach¹⁵
3. circumference – measurement can be taken using a piece of string to outline the shape of the bite, then measure the string¹⁶

If punctures are present:

1. between puncture distance⁵
2. length of the punctures and depth of the deepest point in each puncture – estimate of tooth size, assuming the tooth penetrates to its base¹⁵
3. center to center between punctures or distance between rake lacerations – estimate of the interdental distance^{15,16}
4. a count of tooth punctures⁹

It should be noted that size, morphology, and interdental distance can differ between the upper and lower jaw of sharks^{7,16}. Photos of the shark bite with a ruler present should also be taken to document the location and overall shape of each bite and so that consultation with a shark expert can be done at a later date. Additionally, sharks may lose their teeth while biting potential prey^{9,16}. Thus, care should be taken during necropsy to look for whole shark teeth or fragments in the tissues around the wound site. If whole teeth or tooth fragments are found, size and shark species can more reliably be identified.

If the shark bite wound is healed, it is recommended to take photos of the scar with a ruler present and measure the diameter of the scar if possible; however, this measurement should not be used to determine the size or species of the shark because of reasoning described above regarding inconsistencies with wound healing.

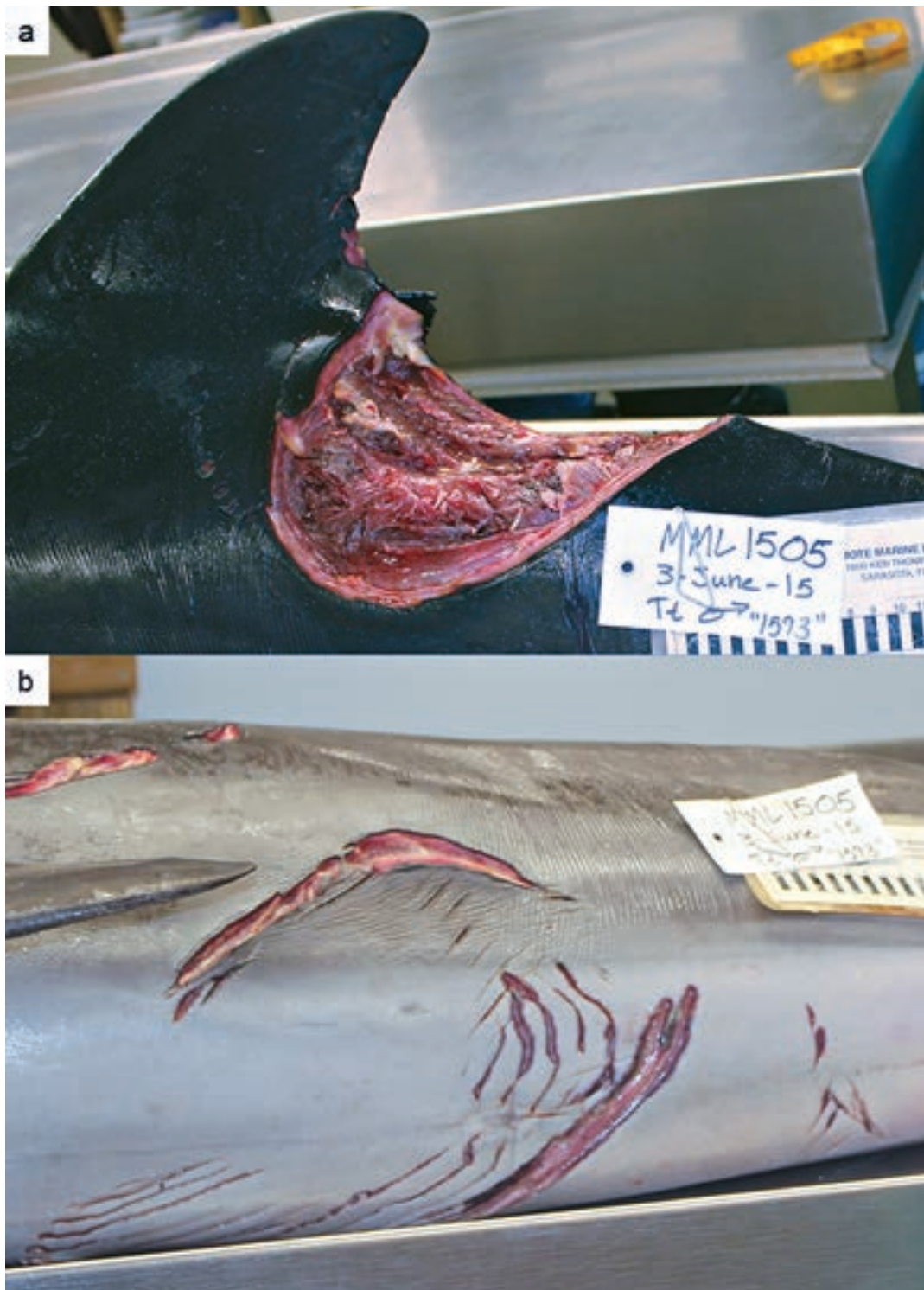

Figure 3. Examples of premortem shark bites on a male common bottlenose dolphin (*Tursiops truncatus*) carcass. Mote Marine Laboratory's Stranding Investigations Program received information from a concerned citizen about a dolphin that was seen alive with several fresh shark bites. Shortly after the call was received, the animal expired on his own. Mote's Stranding Investigations Program collected the carcass and performed a necropsy. Tissue response can be detected from; (a) shark bite posterior to dorsal fin – hemorrhaging present along the blubber-muscle interface and deep red coloration near the skin-blubber interface, muscle is brightly colored; (b) bite wounds on the ventral surface of the animal – hemorrhaging and bruising can be seen along the wounds.

Photo credit: Mote Marine Laboratory's Stranding Investigations Program.

Treatment

No specific treatment for shark bite wounds is indicated for free swimming individuals. If an animal has recently been rescued and is in rehabilitation, treatment may be appropriate if the lesions are recent, open, and bleeding or if there is evidence of infection near the wound site. Studies of Hawaiian monk seals (*Monachus*

schauinslandi) have suggested that dehydration may result following traumatic injuries¹⁷. Therefore, it may be advised that dehydration be monitored in recently rescued animals if fresh shark bite wounds, or other sources of traumatic injury, are present.

Zoonotic potential

Not applicable.

REFERENCE

- Heithaus, M.R. (2001). Predator-prey and competitive interactions between sharks (order *Selachii*) and dolphins (suborder *Odontoceti*): a review. *Journal of Zoology*, 253(1), 53-68.
- Norris, K.S., & Dohl, T.P. (1980). The structure and function of cetacean schools. In L. Herman (ed.) *Cetacean Behavior: Mechanisms and Functions* (pp. 211-261). New York, NY: Wiley.
- Wells, R.S., Irvine, A.B., & Scott, M.D. (1980). The social ecology of inshore odontocetes. In L. Herman (ed.) *Cetacean Behavior: Mechanisms and Functions* (pp. 263-371). New York, NY: Wiley.
- Wells, R.S., Scott, M.D., & Irvine, A.B. (1987). The social structure of free-ranging bottlenose dolphins. In H.H. Genoways (ed.) *Current mammalogy*, Volume 1 (pp. 247-305). New York, NY: Plenum Press.
- Corkeron, P.J., Morris, R.J., & Bryden, M.M. (1987). Interactions between bottlenose dolphins and sharks in Moreton Bay, Queensland. *Aquatic Mammals*, 13(3), 109-113.
- Cockcroft, V.G., Cliff, G., & Ross, G.J.B. (1989). Shark predation on Indian Ocean bottlenose dolphins *Tursiops truncatus* off Natal, South Africa. *South African Journal of Zoology*, 24(4), 205-310.
- Heithaus, M.R. (2001). Shark attacks on bottlenose dolphins (*Tursiops aduncus*) in Shark Bay, Western Australia: attack rate, bite scar frequencies, and attack seasonality. *Marine Mammal Science*, 17(3), 526-539.
- Wilkinson, K.A., Wells, R.S., Pine III, W.E., & Borkhataria, R.R. (2017). Shark bite scar frequency in resident common bottlenose dolphins (*Tursiops truncatus*) in Sarasota Bay, Florida. *Marine Mammal Science*, 33(2), 678-686.
- Long, D.J., & Jones, R.E. (1996). White shark predation and scavenging on cetaceans in the eastern North Pacific Ocean. In A.P. Klimley, & D.G. Ainley (Eds.), *Great white sharks: the biology of *Carcharodon carcharias** (pp. 293-307). San Diego, CA: Academic Press, Inc.
- Corkeron, P.J., Morris, R.J., & Bryden, M.M. (1987). A note on healing of large wounds in bottlenose dolphins, *Tursiops truncatus*. *Aquatic Mammals*, 13(3), 96-98.
- Zasloff, M. (2011). Observations on the remarkable (and mysterious) wound-healing process of the bottlenose dolphin. *The Journal of investigative dermatology*, 131(12), 2503-2505.
- Smith, F., Allen, S. J., Bejder, L., & Brown, A. M. (2018). Shark bite injuries on three inshore dolphin species in tropical northwestern Australia. *Marine Mammal Science*, 34(1), 87-99.
- Melillo-Sweeting, K., Turnbull, S. D., & Guttridge, T. L. (2014). Evidence of shark attacks on Atlantic spotted dolphins (*Stenella frontalis*) off Bimini, The Bahamas. *Marine Mammal Science*, 30(3): 1158-1164.
- Sprogis, K. R., King, C., Bejder, L., & Loneragan, N. R. (2018). Frequency and temporal trends of shark predation attempts on bottlenose dolphins (*Tursiops aduncus*) in temperate Australian waters. *Journal of Experimental Marine Biology and Ecology*, 508, 35-43.
- Martin, R.A. (2003). White shark bite forensics – a photo essay. Retrieved September 17, 2018 from http://www.elasmo-research.org/education/white_shark/forensics.htm.
- Lowry, D., de Castro, A.L.F., Mara, K., Whitenack, L.B., Delius, B., Burgess, G.H., & Motta, P. (2009). Determining shark size from forensic analysis of bite damage. *Marine Biology*, 156(12), 2483-2492.
- Banish, L.D., & Gilmartin, W.G. (1992). Pathological findings in the Hawaiian monk seal. *Journal of Wildlife Diseases*, 28(3), 428-434.

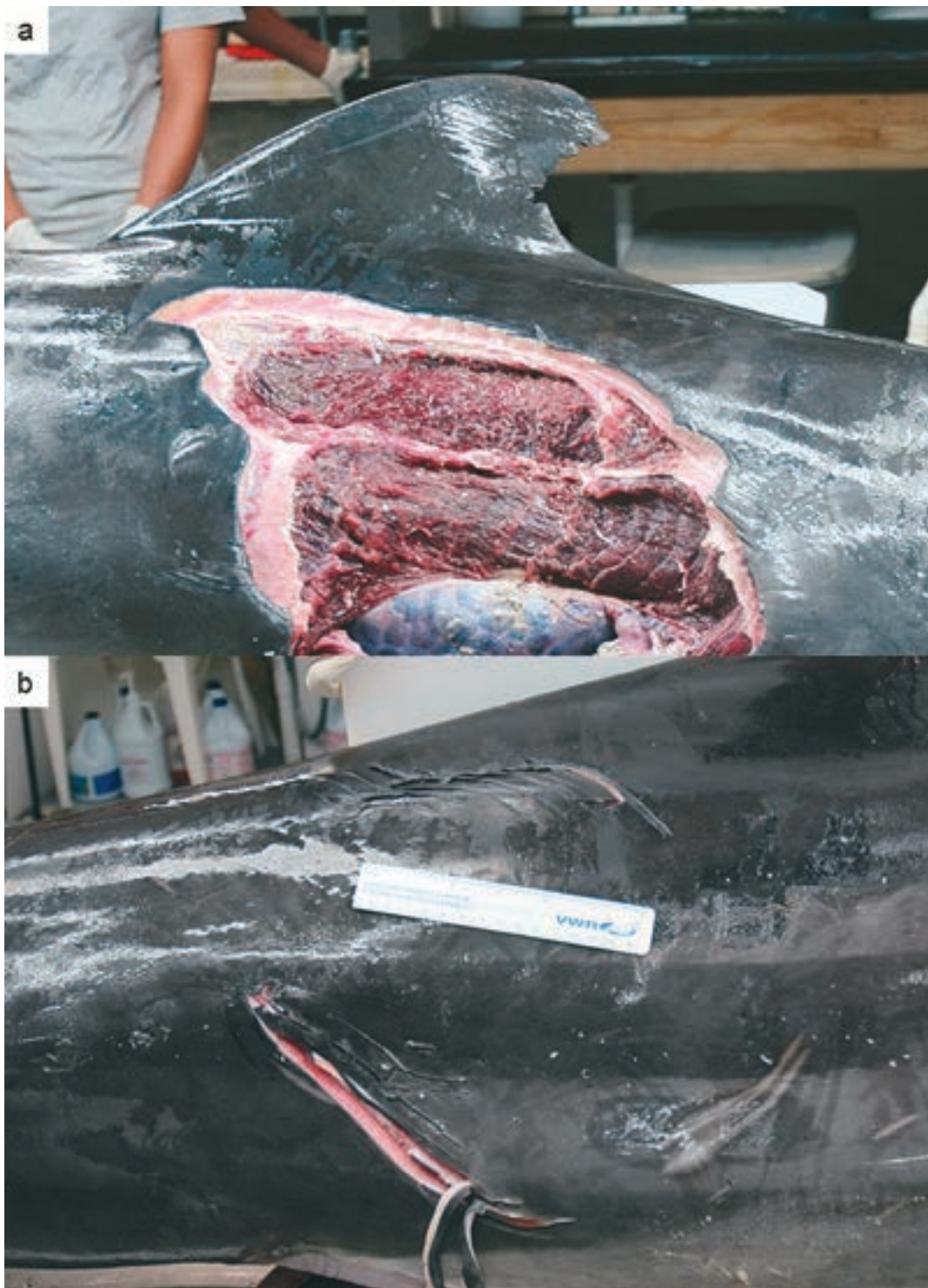


Figure 4. Examples of postmortem shark bites on a female common bottlenose dolphin (*Tursiops truncatus*) carcass. Mote Marine Laboratory's Stranding Investigations Program recovered the carcass and performed a necropsy. In contrast to premortem wounds, tissue response is absent; (a) shark bite on left side of animal – no evidence of congestion, hemorrhaging, or hematoma along the blubber-muscle interface and tissue is white/light pink with little variation, muscle color is dull and greying; (b) bite wound on the right side of the animal near the peduncle – tissue is white/light pink with little variation.

Photo credit: Mote Marine Laboratory's Stranding Investigations Program.

STINGRAY SPINE

Jay Sweeney

Clinical Presentation

Dolphins of many species have been observed to play with objects and organisms that they encounter in their environment. Play is any interaction with an object or organism that includes chase, mouth-hold, toss, nudge, or any sort of interaction, except consume as food. The coastal ecotype of Bottlenose Dolphin, (*Tursiops truncatus*), occupies near shore and shallow estuarine environments along the eastern Atlantic coastline, and that of the Gulf of Mexico. This environment has an amazing diversity of marine and brackish water organisms, some of which are common prey of these dolphins, and some others are known to be objects of play. Among these are several species of sting rays. As there are typically many sting rays that align home ranges with Bottlenose Dolphins, encounters between dolphins and these animals is common. Dolphins typically chase, nudge and contact sting rays with their rostrum. As a consequence of this play behavior, sting ray spine penetration becomes the result of the ‘play’ behavior.

Sting ray spines are located at the base of the tail. Depending on the size of the ray, the spines can vary in length from between 3 cm to 6 cm or more. Both sides of the spine is armed with back leaning barbs that are intended to secure placement of a spine into tissues of a potential predator, like a playful dolphin. This becomes a serious threat to the survivorship of any such playful dolphin.

Typical spine puncture locations on dolphins is anywhere between the dolphins eye and its dorsal fin, owing to the fact that the dolphin is harassing the sting ray’s head, so that the spine thrust then is located to the above area of the dolphin’s body. In many instances, the spine then breaks off of the sting ray tail, being left in the dolphins skin, and/or sub-dermal tissues. This presents two potentially serious problems for the dolphin. These are: 1) the spines are a very good contaminant of marine bacteria; and 2) the backward directed barbs on the spine tend to force the spine to move inward with the dolphin’s body movements. These two factors make for two separate clinical presentations. They are:

1. Cutaneous draining tract, given the presence of a contaminated foreign object. This draining tract often is less than 1 cm in diameter, but is characterized by a continuously pus draining tract (*Figure 1*).

2. The inward movement of the spine over time can lead it to penetration of vital organs. This has been observed at necropsy in many cases.

Diagnostics

As noted above, the clinical presentation of a sting ray spine penetration is the presence of small draining tract in the skin of the dolphin, located anywhere between the eye and dorsal fin. Further diagnostic confirmation can be made utilizing cutaneous diagnostic ultrasound (figure #2). The same can be used to confirm some deeper organ invasion. In the absence of ultrasound equipment, the presence of a sting ray spine, located within reachable distance from the skin surface, can be made by passing a blunt metal surgical probe (2 – 3 mm diameter) into, and along the draining tract, and impacting the tip of the spine.

Treatment

Other than palliative systemic antibiotics, surgical removal of the spine is necessary. Locating the spine, as above, is critical in assessing a surgical plan. With superficial penetration, e.g., location within blubber, fascia or upper margins of muscle tissue, the spine may be removed using a straight surgical hemostat to reach the upper margin of the spine and removing with upward tension. Guiding with simultaneous diagnostic ultrasound greatly helps with this procedure. Spine removal is best guided through the draining tract, as the associated necrotic core makes for easier upward movement against the upward reaching barbs of the spine. For deeper spine location within the skin, a small cutaneous incision will accommodate the larger parts of the hemostat.

For spine migration into body cavities, this author is unaware of such spine so located being removed surgically. At necropsy, some spines have been located within fibrous granulomas, where further penetration and organ damage has been stopped. In other cases, fatal penetrations into lung, liver or other vital organs have been found.

Zoonotic Potential

None

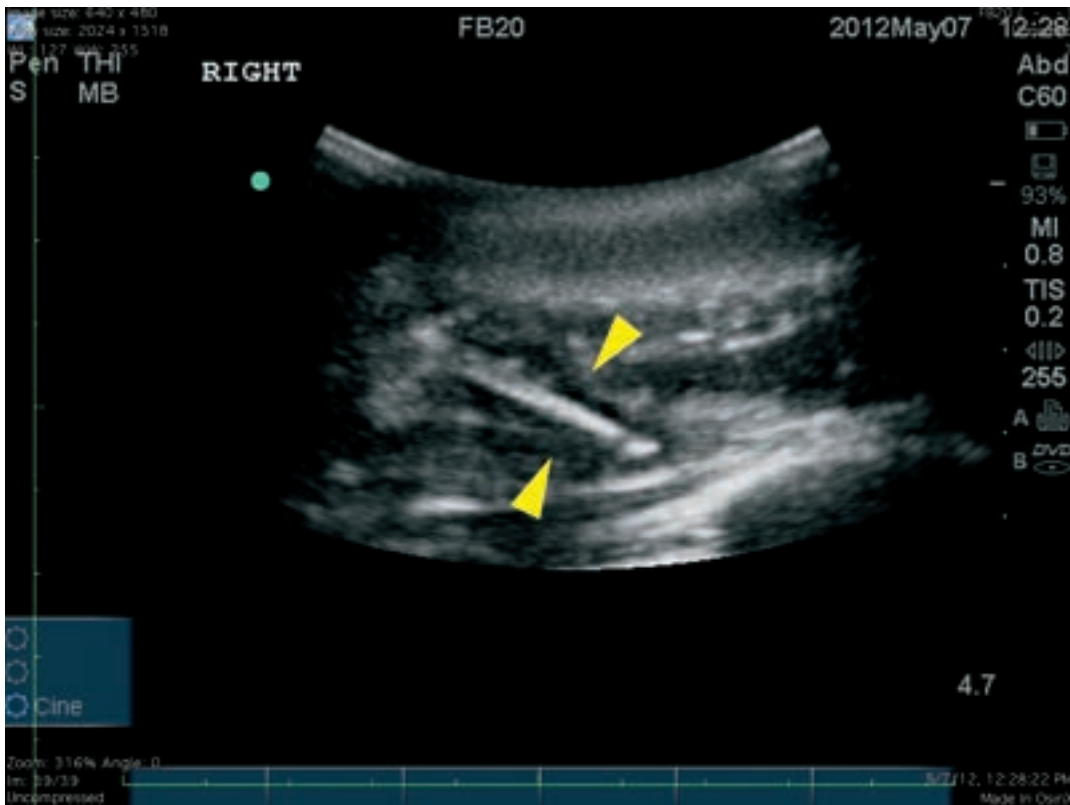


Figure 1. *Ultrasound photograph of the offending sting ray spine that was removed from the dolphin in figure 2. Photo Credit: Dr Cynthia Smith*



Figure 2. *This is the entry wound of the sting ray spine picture above, note the obvious swelling around the wound.*

Inset photo. *A typical sting ray spine found embedded in dolphins Photo credit Wayne McFee*

STRAND FEEDING

Craig A. Harms

Clinical Presentation

Strand feeding is a specialized mode of feeding in which cetaceans intentionally beach themselves to feed on the stranded fish they have herded there, or in pursuit of shore-based prey. It is most commonly described in bottlenose dolphins (*Tursiops truncatus* and *Tursiops sp.*),^{1,2,3,6,7} but also in humpback dolphins (*Sousa plumbea*),⁵ all of which herd fish towards a soft, gently sloping shore and strand them with their bow waves. A large cetacean, the killer whale (*Orcinus orca*), also strand feeds in pursuit of bird and seal prey near the water's edge.⁷ Strand feeding by bottlenose dolphins has been reported in the southern and southeastern United States (especially South Carolina and Georgia, but also Texas and Louisiana), Baja California (both Gulf and Pacific coasts), Portugal, Mauritania, and Shark Bay, Western Australia.^{1,2,3,6,7} Strand-feeding sites for small cetaceans usually have a mud substrate, but occasionally sand or sandy mud. Fish prey identified have included mullet (*Mugil sp.* and *Liza argentea*), menhaden (*Brevoortia tyrannus*), bonefish (*Albula bulpes*), longbottoms (*Tylosurus gavioides*);^{2,5,6,7} other shallow water fishes such as spot (*Leiostomus xanthurus*) and silver perch (*Bairdiella chrysura*) are presumed consumed as well.³ Strand feeding generally occurs around low tide in low visibility waters.^{3,5} It can be an individual or a cooperative venture, with 1 – 6 dolphins per event.^{1,5,7} and social learning of the technique is presumed to occur.^{3,6}

Characteristic skin and dental lesions derive from the predominant orientation during strand feeding, and the repeated asymmetric abrasion that occurs. In North America, bottlenose dolphins engaged in strand feeding usually emerge right side down^(3,4,7), displaying lateralized behavior.⁴ Bottlenose dolphins in Western Australia, and humpback dolphins, apparently strand feed ventral side down.^{5,6} Dermal abrasions with irregular healed lacerations and marked dental wear occur on the side most commonly in contact with the substrate during strand feeding.

Histopathology /Diagnostics

Asymmetrical dermal abrasion, irregular healed lacerations, and marked dental wear to the down side, are characteristics of sustained strand feeding. Lesions for ventral-approach strand feeders apparently have not been described, but presumably would involve ventral rostral abrasions, without asymmetrical dental wear.

Treatment

No specific treatment for skin lesions is indicated, unless, possibly, if the lesions are recent, open and bleeding in a recently rescued animal in rehabilitation. Treatment of associated dental lesions would be indicated if open roots are present.

Zoonotic potential

Not applicable.

REFERENCE

- Duffy-Echevarria, E.E., Connor, R.C., and St. Aubin, D.J. (2008) Observations of strand-feeding behavior by bottlenose dolphins (*Tursiops truncatus*) in Bull Creek, South Carolina. *Marine Mammal Science* 24(1): 202-206.
- Fox, A.G., and Young R.F. (2012) Foraging interactions between wading birds and strand-feeding bottlenose dolphins (*Tursiops truncatus*) in a coastal salt marsh. *Canadian Journal of Zoology* 90: 744-752.
- Hoese, H.D. (1971) Dolphin feeding out of water in a salt marsh. *Journal of Mammalogy* 52(1): 222-223.
- Marino, L., and Stowe, J. (1997) Lateralized behavior in two captive bottlenose dolphins (*Tursiops truncatus*). *Zoo Biology* 16: 173-177.
- Peddemors, V.M. and Thompson, G. (1994) Beaching behaviour during shallow water feeding by humpback dolphins *Sousa plumbea*. *Aquatic Mammals* 20.2: 65-67.
- Sargeant, B.L., Mann, J., Berggren, P., and Krützen, M. (2005) Specialization and development of beach hunting, a rare foraging behavior, by wild bottlenose dolphins (*Tursiops sp.*). *Canadian Journal of Zoology* 83: 1400-1410.
- Silber, G.K., and Fertl, D. (1995) Intentional beaching by bottlenose dolphins (*Tursiops truncatus*) in the Colorado River Delta, Mexico. *Aquatic Mammals* 21.3: 183-186.



Figure 1: This is a photograph of four *Tursiops truncatus* strand feeding in a creek on the Atlantic coast. These dolphins have “herded” a school of mullet up on a shallow mud bank and have themselves move on the mud bank to catch the flopping fish (above). Notice that all four are on their right sides. The photo below is the face of one of these strand feeders showing the scars caused by the oyster shells and other debris found in these areas. Along with the skin lesions, there are often broken and missing teeth on the right mandibles and maxilla arcades and traumatic corneal lesions in their right eyes. Permit number: MMPA Permit No. 779-1633-00. Photo credit: NOAA



Figure 2: Permit: Scientific Research Permit No 960. Photo credit: NOAA

CHAPTER SEVEN: MICELLANEOUS

EMACIATION

Julie M Cavin

Clinical Presentation

Body condition assessment is paramount to establishing the health status of cetaceans whether free-swimming, stranded or under human care. Body condition can be quantified as emaciated, thin, healthy, or obese. Decreased body condition (thin or emaciated) may indicate decreased nutrition, illness, or an indirect signal of disease or exposure to environmental hazards and is a negative prognostic indicator for survivability.¹

Body condition can be determined by analyzing four landmarks along the body: the nuchal crest just posterior to the blowhole, the base of the dorsal fin, the thoracic wall and the peduncle.²⁻⁴ A post-nuchal depression has been found to be one of the most reliable signs of emaciation in cetaceans.^{3,4} This condition is often referred to as “peanut-head” due to the narrowing between the larger head and trunk. The next most reliable indicator of emaciation is the wasting of the epaxial region at the base of the dorsal fin. In severe cases of muscle loss, the lateral insertions of the dorsal fin to the body can be observed on either side of the fin base. These dorsal concavities can easily be observed from several vantages (aerial, side view, etc.) and are often the most useful parameters for swimming animals as the blowhole and dorsal fin regions may be seen when breathing or resting at the surface. Two more signs of poor body condition are the overall narrow shape of the body creating an almost

elongated triangular appearance and the visibility of the ribs or scapula in the thoracic region and/or the lateral vertebral processes along the peduncle. While these parameters are more difficult to assess in a swimming animal, if present, they help confirm a body condition of emaciation.

Animals become thin or emaciated by consuming too few nutrients to meet the need for normal bodily functions. Blubber and muscle lipid and proteins are catabolized for energy which leads to the wasting appearance. Along with normal organ function, poor nutritional status also inhibits the ability to heal. Emaciated cetaceans are sometimes observed with chronic wounds potentially due to a negative nitrogen balance. Nitrogen is required for synthesis of proteins that make up collagen (one of the structural components of blubber), muscle fibers and essential elements necessary for wound healing.⁵

Diagnosis

Persons familiar with dolphin anatomy can readily determine an obese dolphin from an underweight individual. It is those that fall between these extremes that can be difficult to evaluate. There has been developed a formula to assess body condition in *Tursiops truncatus*. This assessment requires total mass by weighing the animal in a sling, while maximum girth is the circumference of the body just anterior

REFERENCE

1. Sharp SM, JS Knoll, MJ Moore, KM Moore, CT Harry, et al. 2013. Hematological, biochemical, and morphological parameters as prognostic indicators for stranded common dolphins (*Delphinus delphis*) from Cape Cod, Massachusetts, USA. *Mar Mamm Sci.* 30(3): 864-887
2. Bradford AL, DW Weller, AE Punt, YV Ivaschenko, AM Burdin, et al. 2012. Leaner leviathans: body condition variation in a critically endangered whale population. *J Mammal.* 93(1): 251-266.
3. Joblon MJ, MA Pokras, B Morse, CT Harry, KS Rose, et al. 2014. Body condition scoring system for Delphinids based on short-beaked common dolphins (*Delphinus delphis*). *J Mar Anim Ecol.* 7(2): 5-13.
4. Pettis HM, RM Rolland, PK Hamilton, S Brault, AR Knowlton, SD Kraus. 2004. Visual health assessment of North Atlantic right whales (*Eubalaena glacialis*) using photographs. *Can J Zool.* 82: 8-19.
5. Hand MS, CD Thatcher, RL Remillard, P Roudebush (eds). 2000. *Small Animal Clinical Nutrition, fourth edition*. Mark Morris Institute. Pp 48-56..

to the dorsal fin. Total length is measured from the upper rostrum tip to the fluke notch, are combined with the total mass to compute body mass index (BMI)^{6,7}. Determination of body condition from obese to emaciated can be made via personal observation or photographs taken of free swimming, stranded or deceased animals.

Treatment

Improved nutrition and treatment of the underlying cause of illness whether infectious or non-infectious is required to attempt to return the emaciated individual to a healthy body weight.



Figure 1: Emaciated melon-headed whale (*Peponocephala electra*) with post-nuchal depression (peanut head), visible scapula, and epaxial wasting. Photo courtesy of Gulf World Marine Institute.



Figure 2: Harbor porpoise (*Phocoena phocoena*) with post-nuchal depression and severe epaxial wasting. Photo courtesy of New England Aquarium.

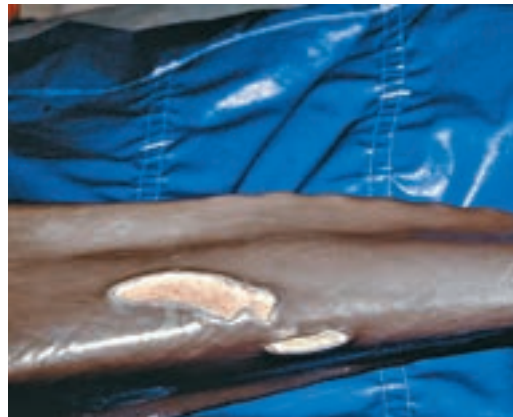

Figure 3: Emaciated adult bottlenose dolphin (*Tursiops truncatus*) with obvious lateral vertebral processes and non-healing wounds. Photo credit Forrest Townsend.



Figure 4: Prominent lateral vertebral processes along the peduncle, and epaxial wasting in false killer whale (*Pseudorca crassidens*). Photo credit Brian Balmer

EXPOSURE DERMATITIS

Ashley Barratclough

Severe dermatological changes have been observed in dolphins exposed to the elements for prolonged periods of time including UV rays, wind, hypothermia and extreme drying. Currently the most frequent cause of exposure dermatitis is in stranded cetaceans, which are dry docked on the beach for some time. It appears however that the cause of the damaged epidermis is multifactorial rather than just UV damage from sunburn with extreme drying out of the skin and hypothermia also contributing.^{1,2}

Clinical Presentation

Sunburn-like dorsal lesions have been described in both wild animals and in those under human care.³ Extreme damage has been observed in stranded cases in poor weather conditions where minimal UV was present confirming the likelihood of a multifactorial etiology. Fissures around the blow hole are also believed to be a result of drying.⁴ Biopsy to confirm the underlying pathophysiology is rarely taken in wild animals leading to the presumptive diagnosis of sunburn, dehydration and skin sloughing.⁵ The innate healing capability of dolphin skin is quite remarkable as many other species with such extensive injuries would likely

succumb to sepsis without surgical and/or therapeutic intervention.^{6,7}

Prevention / Treatment

Cetaceans in rehabilitation facilities can present with positive buoyancy issues (continually exposed head or dorsal regions) and have therefore presented with similar dermatological lesions.⁸ Providing shade, spraying the skin to keep it moist and even applying zinc based sun screen has been used to prevent damage (*Figure 1*).⁹ Covering skin with wet towels or even seaweed is recommended in stranded cases to prevent drying out and UV exposure (*Figure 2*). Despite extensive lesions being reported in stranded animals the photo series (*Figure 3*) of a dolphin which stranded along the coast of Scotland shows how an extensive lesion resolved with it fully healed two years later. The extent of this lesion could influence the decision of stranding responders to recommend euthanasia instead of release or rehabilitating the animal. This case series over two years provides photographic evidence of appearance, progression and resolution of a large area of exposure dermatitis.

REFERENCE

- Ridgway S. Homeostasis in the aquatic environment. *Mammals of the Sea* 1972;590-747.
 - Greenwood A, Harrison R, Whitting H. Functional and pathological aspects of the skin of marine mammals. *Functional anatomy of marine mammals* 1974;2:73-110.
 - Bloom P, Jager M. The injury and subsequent healing of a serious propeller strike to a wild bottlenose dolphin (*Tursiops truncatus*) resident in cold waters off the Northumberland coast of England. *Aquatic Mammals* 1994;20:59-59.
 - Simpson JG, Gardner MB. Comparative microscopic anatomy of selected marine mammals *Mammals of the Sea, Biology and Medicine* 1972;ed. Ridgway, S.H.:298-418.
 - Bossley MI, Woolfall MA. Recovery from severe cutaneous injury in two free ranging bottlenose dolphins (*Tursiops spp.*). *Journal of Marine Animals and their Environment* 2014;7:12-16.
 - Riggin JL, Maldini D. Photographic case studies of skin conditions in wild-ranging bottlenose dolphin (*Tursiops truncatus*) calves. *Journal of Marine Animals and their Ecology* 2010;3:5-9.
 - Zasloff M. Observations on the remarkable (and mysterious) wound-healing process of the bottlenose dolphin. *The Journal of investigative dermatology* 2011;131:2503-2505.
 - Brown DH, McIntyre R, Delli Q, et al. Health problems of captive dolphins and seals. *Journal of the American Veterinary Medical Association* 1960;137:534-538.
 - Gulland FM, Dierauf LA, Whitman KL. *CRC handbook of marine mammal medicine*. CRC Press; 2018.
- "Sprite" Spotted nearly 500 miles away on the coast of Ireland. <https://www.bbc.com/news/uk-scotland-highlands-islands-48989217>



Figure 1. Shows a stranded goose beaked whale with sun cream applied during rehabilitation to prevent exposure dermatitis from positive buoyancy.

Figure 2. Spiritle stranded on May 29th, 2016, towels and sea weed were used to cover the exposed skin.



This photo was taken on July 14th, 2016 just under two months after the stranding.



On September 7th, 2016 there is significant granulation tissue and contracture of the wounds.



This is one year post stranding taken on July 27th, 2018.



This photo taken on July 27th, 2018 two years after the stranding.

Photo credit University of Aberdeen, Barbara Cheney and Charlie Phillips,
Whale and Dolphin conservation Society

PROLONGED FRESHWATER EXPOSURE

Forrest I. Townsend, Jr.

Clinical Presentation

When marine dolphins find themselves in varying degrees of fresh water (less than 11 PPT salinity), obvious skin lesions can appear along with physiological changes in their blood values.¹

“Out of habitat” (OOH) is the term used when dolphins find themselves in low salinity environments. This can occur when climatic events, such as hurricanes or excessive rainfall, lowers the salinity. Included in these events, is when rapidly rising and falling water levels displace animals into bodies of fresh water.³ Man made causes can occur when breeches in impoundments, canals, levees, or other freshwater bodies of water are repaired and “unlucky” dolphins are found on the wrong side. Curiously, there are also situations wherein dolphins have free access to more saline waters but remain in very low saline waters; therefore, developing the obvious skin lesions of fresh water exposure.

The visual skin lesions resulting from hydropic degeneration include excessive, irregular skin sloughing, often appearing in circular patterns (Pensacola case photo). In time, secondary opportunistic pathogens (viral, bacterial, mycotic) can become involved, changing the appearance of the gross lesions. Some dolphins have a uniform light grey coloration over the body early in the disease process. (Figure 1). Clouding of the eye is often observed from corneal edema. Left in very low salinity for extended periods of time can result in death.

When interventions are made and blood samples analyzed, the primary changes seen are significantly lower serum sodium and chloride levels. Serum osmolality and alkaline phosphatase are lower as well. The lower serum alkaline phosphatase levels may be caused by poor nutrition from lack of familiar prey fish or anorexia from the disease².

Histopathology /Diagnostics

The presumptive diagnosis often rely on the history of prolonged fresh water exposure. However, when biopsies are obtained from the lesions the histopathology only reveals mild changes in the integument. Secondary pathogens can be observed as in the skin biopsy photo on page 12.

Treatment

Transporting the out of habitat individual(s) to adequate saline waters will result in improvement of the skin/eye lesions and the abnormal blood values. The animals whose health appear significantly compromised based on preliminary blood analysis or physical examination may be brought to a rehabilitation facility. (Sarasota before and after dolphin photos). After they recover from their disease, hopefully, they can be released back into the wild.

Zoonotic potential

Not applicable.

REFERENCE

1. Ewing R, Mase-Guthrie B, McFee W, Townsend F, Manire C, Walsh M, Borkowski R, Bossart G, Schaefer A. Evaluation of Serum for Pathophysiology of Prolonged Low Salinity Water Exposure in Displaced Bottlenose Dolphins (*Tursiops truncatus*), *Journal. Frontier in Veterinary Science*, 08 June, 2017.
2. Mase-Guthrie B, Townsend F, McFee W, Manire C, Ewing RY, and Pitchford T. Cases of prolonged freshwater exposure in dolphins along the Southeast United States. Poster presentation at Society for Marine Mammalogy 16th Biennial Conference, San Diego, CA (2005).
3. Mullin KD, Barry K, Sinclair C, Litz J, Maze-Foley K, Fougères E, et al. Common bottlenose dolphins (*Tursiops truncatus*) in Lake Pontchartrain, Louisiana: 2007 to mid-2014. NOAA technical Memorandum NMFS-SEFSC-673. (2015).43p.



MMPA/ESA Permit No. 18786-1

Figure 1: *Note the general pallor of the skin due to prolonged exposure to low salinity.*



Figure 2: *A severe case of prolong freshwater exposure from Pensacola Bay, FL.*

Galveston Bay Dolphin ID# 209

Timeline showing the manifestation of skin lesions on an individual bottlenose dolphin in upper Galveston Bay, Texas. The surface salinity at the time of the sighting is noted on each photo.

Salinity profile represents monthly average surface salinity (ppt) within dolphin #209's observed range 2015 - 2017




Figure 3: Photos courtesy of Kristi Lynn Fazioli

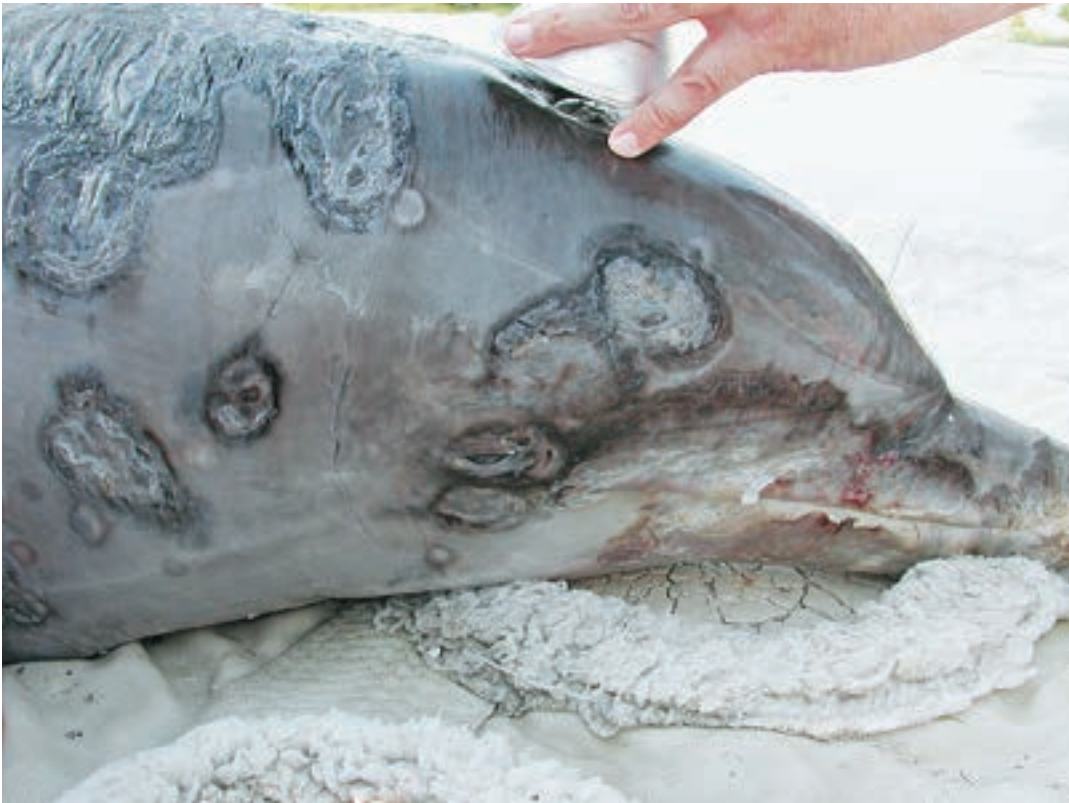

Figure 4: Before and after photos of freshwater exposure and healing in a stranded dolphin in rehabilitation at Mote Marine Lab, Sarasota, FL.



Figure 5: After one month in rehabilitation with resolving skin lesions.

HYPOPIGMENTATION IN SMALL CETACEANS

Michael T. Walsh

There is a wide variety of pigment color variations in small cetaceans. These include hyperpigmentation, full body loss of pigment (melanin), hypopigmentation isolated to discreet anatomic sites, regional, patchy, or generalized decreases in pigment. Expressions of hypopigmentation may be the result of a number of etiologic factors. In a number of cetacean species skin color may change from grey to light grey to pink as individuals age, with genetic variations such as albinism and leucism. Loss of pigment may be secondary to skin trauma or scarring, local or systemic infection, changes in environmental parameters, toxins or even medication that influences the melanin normally found in the skin.

Natural Developmental Hypopigmentation

While many are familiar with the color change that young belugas go through from dark grey to their adult white color this also occurs in other cetacean genus. The Souza genus is comprised of the Souza *chenensis* (Indo-Pacific humpback dolphin) and Souza *plumbea*, the Indian Ocean humpback dolphin, and Souza *sahulensis* the Australian humpback dolphin. Coloration of this species ranges from grey to white to pink with the species west of India the calves start as a light grey then becoming darker while those calves east of India starting as darker grey then becoming whiter or pink with age. Spot development is part of the transition to a more consistent full body hypopigmentation with spots as shown in a mother calf pair of Souza *chinensis* (Figure 1). In the Atlantic the Amazon River dolphin (*Inia geoffrensis* or *boto*) is another species that has a wide variation in color with the young dark grey dorsally and lighter grey laterally morphing to variations in pink as they mature.

Anomalous Genetic Expressions of Hypopigmentation

Melanin is a pigment that produce most of the color seen in mammals. The production of melanin is dependent on the enzyme tyrosinase in the melanocytes based on the presence of TYR gene. If this gene is damaged or absent then the animal develops as an albino with pink eyes and white skin, hair or fur. The differentiation between true albinism and leucistic coloration is based on the presence of any pigment in the body including the iris. Leucistic coloration with

brown iris is the result of a recessive gene donated from both parents where the skin is missing the melanin, but the eyes are still pigmented. While the expression of true albinism is rare it has been seen in cetaceans such as bottlenose dolphins. Fertl reviewed over 20 species of full body white cetaceans that have been observed including small species such as Heaviside's dolphin (*Cephalorhynchus*), Common dolphin (*Delphinus*), Atlantic and Pacific white sided, and Dusky dolphin (*Lagenorhynchus*), Bottlenose (*Tursiops*), Rough toothed (*Steno*), Atlantic spotted and Spinner dolphin (*Stenella*), Harbour porpoise (*Phocoena*), and Dall's porpoise (*Phocoenoides*)^{1,2,3,4,5,6}. In the Gulf of Mexico different sightings of hypopigmentation in Tursiops have occurred at Louisiana, Mississippi and Texas and then in 2003 and 2004 with the most recent on social media. In 1994 a white dolphin was observed in the Gulf of Mexico and was reported to have pink eyes.^{1,2} Many of these variations are wild observations and the observers are not able to verify if they are true albinos with no eye pigment. An albino tursiops has been kept at the Taji Whale Museum in Japan and appears in photos to have pink iris. A possible albino tursiops has been spotted on multiple occasions in Louisiana, with one of the latest reports in 2017 with video showing her riding the bow wave of a large ship. The animal has been photographed consistently over years by wildlife photographer Capt. Eric Rue and is known as Pinky (Figure 2). There is no confirmation that the animal has non-pigmented iris so at this point is assumed to be leucistic.

In 1964 off the west coast of Florida a local *Tursiops truncatus* population was shown to have "blond" dolphins near Steinhatchee Florida and a female was captured and taken to Marineland of Florida to be joined in 1967 by a male with the lighter color variation. Figure 3 shows the blond female compared to another dolphin of normal color. This variation is thought to be a recessive gene and still present in the wild with a recent sighting.

Hypopigmentation Related to Illness, Injury, Intoxication

Cetaceans may show isolated, patchy, regional or full body pigment changes due to a number of factors impacting the skin. Focal infections can result



Figure 1: *Sousa chinensis* mother and calf. Photo courtesy of Thailand Department of Marine and Coastal Resources



Figure 2. Close-up of *Tursiops truncatus* Pinky in Louisiana 2012. Photo courtesy of Capt. Eric Rue.

in changes in the skin color at the lesion site or in larger areas of the body when an animal is debilitated, systemically ill or chronically entangled. Discreet or diffuse lesions are seen in large whales that are in poor body condition with patchy to diffuse skin texture and color change.⁷

Small to large areas of dermatitis or skin eruptions with lesions from Lacaziosis (also known as Lobo's) may affect the melanin in the skin (*Figure 4*). This condition is a possible zoonotic disease and personal protective equipment should be used.⁸

Rake marks, large wounds from shark attacks and severe sunburns (*Figure 5*) may result in loss of normal pigment or permanent hypopigmentation if the condition is chronic or severe. The longer the damaged area takes to heal, the more white scarring may occur. Chronic skin damage associated with older aged dolphins, repetitive injury or activity such as fishing techniques where the rostrum, pectoral flippers and tail are abraded, will result in a loss of pigmentation (*Figure 6, 7*).

Intoxication with zinc can result in copper deficiency resulting in a decrease in tyrosinase necessary for the synthesis of melanin pigments. A young dolphin with zinc intoxication shows a whole-body loss of melanin in figures 8 and 9. This has also been seen in primates with zinc intoxication.⁹

Hypopigmentation From Fresh Water Exposure

Clinical cases of pigmentation change may be impacted by environmental factors that are out of the normal physiologic range of the cetacean. Excessive cold or increased exposure to temperatures near the low range of tolerance may affect the cetaceans body condition and local skin immunity increasing the number of lesions, their distribution, and the healing rate. Melanin deposition may be temporarily impaired until the environment improves.

Cetaceans may be found in a variety of salinity levels from fresh to sea water with the ability to endure temporary changes in saline shifts. Species evolved for seawater that travel into fresh water rivers for extended periods are considered out of habitat. If trapped in other fresh water areas from storms or tides they may show hyponatremia effects systemically as well as variable ocular and epidermal-dermal changes (*Figure 10*). The skin changes will become more severe over time with disruption of epidermal integrity, regional and whole-

body hypopigmentation, epidermal ulceration and secondary infections of algae, fungal, viral and bacterial growth (*Figure 11*) in the compromised skin. If returned to normal salinity the lesions will heal with normal pigmentation.

Hypopigmentation and Megesterol Acetate

The incidence of medically related hypopigmentation is not well documented. One report describes a decrease of the normal skin pigment level in a male bottlenose dolphin (*Tursiops truncatus*) that was maintained on low levels of megestrol acetate (MA) for several years.⁹ The prolonged MA therapy was also associated with suppressed levels of plasma adrenocorticotrophic hormone (ACTH) and cortisol. The dolphin developed multifocal patchy areas of moderate to severe hypopigmentation, with the most prominent regions affected included the eyelids; the dorsal surface of the fluke blades and the lateral surface of the tail, bilaterally (*Figures 12 a and b*). The areas of affected hypopigmented skin remained intact, were nonpainful; and were not associated with any underlying ulcers or other lesions. The animal remained clinically normal during this time period.

After discontinuing the megestrol acetate, the blood cortisol and ACTH concentrations returned to baseline within 2 months, and the hypopigmentation resolved approximately 22 months later. (*Figures 12 c*) The manifestation of hypopigmentation was consistent with compromised production of tropic hormones at the level of the pituitary gland. Melanocyte-stimulating hormone and ACTH, both of which originate in the pituitary, share a common precursor (proopiomelanocortin). Both compounds can affect skin pigmentation by binding to melanocortin receptors, and both have been implicated in disorders of skin pigmentation.

Acknowledgments

The author is very grateful for the many contributors to this section including our colleagues at Hubbs-SeaWorld Research Institute, SeaWorld Orlando, SeaWorld San Diego, Department of Marine and Coastal Resources Thailand, the US Navy Marine Mammal Program, The National Marine Mammal Foundation, Clearwater Marine Aquarium, Captain Eric Rue of Calcasieu Charter Service, Lake Charles Louisiana.

This is a SeaWorld Parks and Entertainment technical contribution number 2019-2



Figure 3. *Tursiops truncatus* blond dolphin Photo courtesy of Marineland, Marineland Florida.



Figure 4. *Lacaziosis (lobomycosis)* with depigmentation of portions of the area. Lesions may be fully depigmented and occur on the appendages as well. Photo courtesy of Catalina Londona Carder Hubbs-0738-Tt




Figure 5. Third degree sunburn healing in a stranded bottlenose dolphin with areas of hypopigmentation. Photo courtesy of Clearwater Marine Aquarium.

Figure 6. Hypopigmentation of the dorsal fin leading edge from multiple contact injury. Photo credit: NOAA

Figure 7. Rostral hypopigmentation from chronic repetitive local injury. Photo credit: NOAA

REFERENCE

- Fertl, D., Pusser, L. T., Long, J. J. First record of an albino bottlenose dolphin (*Tursiops truncatus*) in the Gulf of Mexico, with a review of anomalously white cetaceans. *Marine Mammal Science*. 15(1):227-234, 1999
- Fertl, D., Barros, N. B., Rowlett, R. A., Estes, S., Richlen, M. An update on anomalously white cetaceans, including the first account for the pantropical spotted dolphin (*Stenella attenuata graffmani*) *LAMAM* 3(2):163-166, 2004
- Stockin, K.A., Visser, I.N. Anomalously Pigmented Common Dolphins (*Delphinus Anomalously Pigmented Common Dolphins* (sp.) off Northern New Zealand. *Aquatic Mammals* 2005, 31(1), 43-51, DOI 10.1578/AM.31.1.2005.43
- Alves, F., Ferreira, R., Dias, L., Nicolau, C., Sousa, D., Moura, C., Gomes, C. Dinis, A. Rare records of hypo- and hyper-pigmented individuals in two delphinid species off Madeira island. *Hystrix, Italian Journal of Mammalogy* Volume 28(1):116-118, 2017
- de Boer M.N. First record of a white rough-toothed dolphin (*Steno bredanensis*) off West Africa including notes on rough-toothed dolphin surface behavior. *Marine Biodiversity Records*, page 1 of 4. # Marine Biological Association of the United Kingdom, 2010 doi:10.1017/S1755267210000539; Vol. 3; e66, 2010
- dos Santos, R. P., Simião, S., Madruga, P., Mendonca, A.S., Seitre, R., Gomes-Pereira, J. Anomalously White Atlantic Spotted Dolphins (*Stenella frontalis*, Cuvier, 1892) Off the Azores. *Aquatic Mammals*. June DOI: 10.1578/AM.42.2.2016.24,2016
- Hamilton, P. K., Mar, M.K. Skin lesions on North Atlantic right whales: categories, prevalence and change in occurrence in the 1990s. *Dis Aquat Org* Vol. 68: 71-82, 2005
- Noke Durden, W., St. Leger, J., Stolen, M., Mazza, T., Londono, C. Lacaziosis in bottlenose dolphins (*Tursiops truncatus*) in the Indian River Lagoon. *Journ. Wildlife Diseases*, 45(30): 849-856, 2009
- Markham, A.C., Gesquiere, L.R., Bellenger, J-P., Alberts, S.C., Altman, J. White Monkey Syndrome and Presumptive Copper deficiency in wild savannah baboons. *Am J Primatol*. 73(11): 1160-1168. 2011 doi:10.1002/ajp.20983



Figure 8. *Hypopigmentation due to zinc intoxication with secondary copper deficiency.*

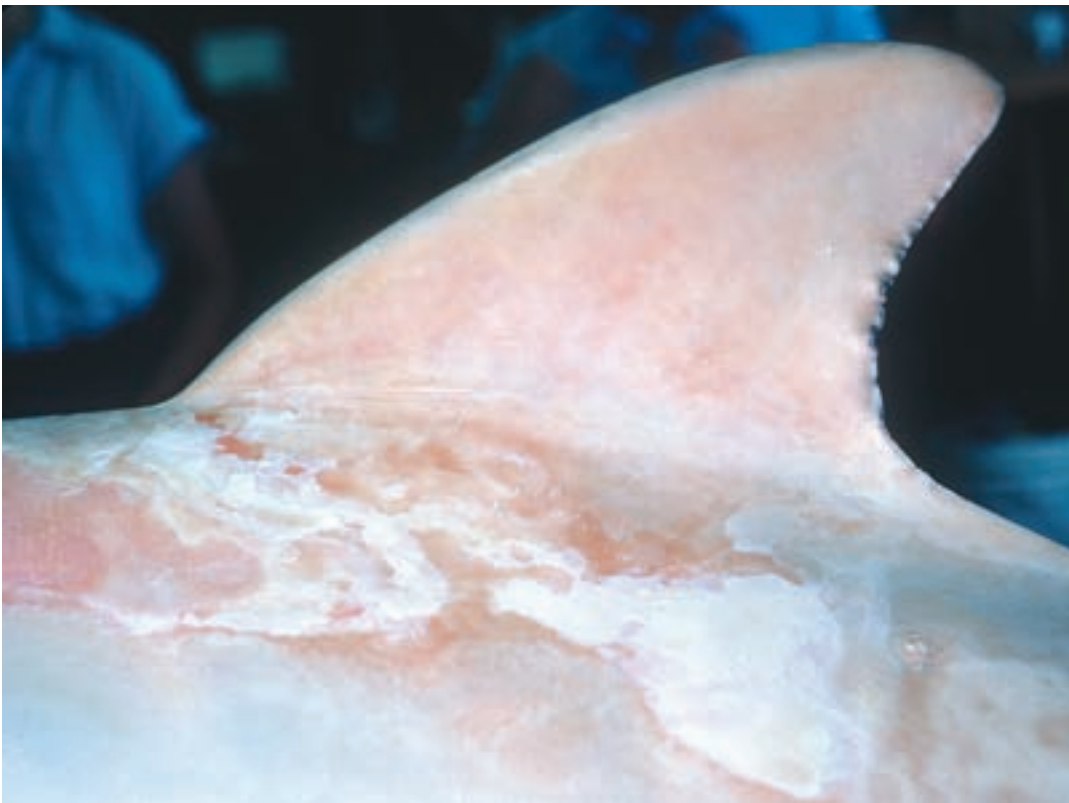

Figure 9. *Zinc intoxication lateral body and dorsal with possible secondary sun effects.*



Figure 10. *Zonal loss of pigmentation anterior body with fresh water or low salinity exposure.*



Figure 11. *Chronic fresh water exposure with severe epidermal disruption and epibiota in areas of damaged skin*



Figure 12. Pale skin associated with chronic use of megestrol acetate. Note the regions of hypopigmented skin affecting the eyelids (12a); and the fluke blades (12b). Photo credit Navy Marine Mammal program

Figure 12c. After discontinuing the megestrol acetate, the hypopigmentation resolved approximately 22 months later. Photo credit Navy Marine Mammal program

SKELETAL MALFORMATIONS

Gretchen N. Lovewell

Clinical Presentation

Skeletal malformations such as scoliosis and kyphosis, and lordosis has been observed in free ranging cetaceans (Berghan and Visser, 2000, Bertulli et al. 2015), post-mortem examination (Watson et al., 2004) and studies of museum collections (Kompanje, 1999). These conditions take two general forms, congenital (*Figure 1*) and idiopathic (*Figure 2*). Congenital deformities result from an embryonic developmental abnormality and persist throughout life. Idiopathic changes have been associated with trauma such as fishing line entanglements and con-specific aggression (Watson et al., 2004), muscle damage from stranding (Geraci and St. Aubin, 1987) or improper transport (Spotte et al., 1979). Idiopathic cases can present as a chronic or be more acute (*Figure 3*) as in the case of a stranding event (Sweeny and Ridgway 1975). Regardless of the etiology, these malformations are typically characterized in three ways: scoliosis is described as an s- or c-curved deviation from the dorsal plane producing a lateral curvature; kyphosis is defined as a deviation of the sagittal plane dorsally, producing a ventral concavity (or “hump”); lordosis is the opposite of kyphosis, thus the abnormal deviation produces a concavity on the dorsal side of the sagittal plane

(Noden and deLahunta, 1985). These malformations are not mutually exclusive and cetaceans can present multiple deformities.

Histopathology/Diagnostics

Skeletal malformations can often be diagnosed by visual exam and/or radiology. Dolphins can develop scoliosis acutely, especially in rehabilitation settings.

Even with relatively severe cases, dolphins have been documented to live “normal” lives, as was the case of FB99 with congenital scoliosis and FB78 with idiopathic scoliosis (DeLynn et al. 2011, Wells and Scott, 1997, R. Wells, personal communication). While the skeletal changes were noteworthy in both cases, neither the extent nor etiology of the deformity was immediately obvious prior to necropsy and skeletal preparation, thus diagnostics can be challenging in more chronic cases.

Treatment

Contrary to the observations made in 1975, dolphins have been documented living in the wild for decades without treatment or intervention. When an animal becomes “bent” through a stranding event or

REFERENCE

- Berghan, J., and I.N. Visser. Vertebral column malformations in New Zealand delphinids with a review of cases world wide. *Aquatic Mammals* 26: 17-25, 2000
- Bertulli, C.G., A. Galatius, C.C. Kinze, M.H. Rasmussen, R. Deaville, P. Jepson, E.J. Vedder, G.J. Sánchez Contreras, R.C. Sabin, A. Watson. Vertebral column deformities in white-beaked dolphins from the eastern North Atlantic. *Diseases of Aquatic Organisms*, Vol 111:59-61, 2015.
- DeLynn, R., G. Lovewell, R.S. Wells, and G. Early. Congenital scoliosis of a bottlenose dolphin. *Journal of Wildlife Diseases*. 41:4 979-983, 2011.
- Geraci, J. R., and D. J. St. Aubin. Cetacean mass strandings: A study into stress and shock. In Proceedings of the 7th Biennial Conference on the Biology of Marine Mammals. Society of Marine Mammology, Miami, Florida, pp. 25, 1987.
- Kompanje, E. J. O. Considerations on the comparative pathology of the vertebrae in Mysticeti and Odontoceti; evidence for the occurrence of discarthrosis, zygarthrosis, infectious spondylitis and spondylorthritis. *Zoologische mededeeligen* 73: 99-130, 1999.
- Norden D., and A. de Lahunta. The embryology of domestic animals, developmental mechanisms and malformations. Williams & Wilkins, Baltimore MD, 1985.
- Rhinehart, H. L., C. A. Manire, and E. L. Brown. “Treatment of a functional scoliosis in a stranded common dolphin (*Delphinus delphis*).” Annual conference-American Association of Zoo Veterinarians. *American Association of Zoo Veterinarians*; 1998, 2000.
- Spotte, S., C.W. Radcliffe, and J. L. Dunn. Notes on Commerson’s dolphin (*Cephalorhynchus commersonii*) in captivity. *Cetology* 35: 1-9, 1979.
- Sweeny, J.C. and S.H. Ridgway. Common diseases of small cetaceans. *Journal of the American Veterinary Medical Association*, Vol.167, No. 7, 533-540, 1975.
- Watson, A., R. Bahr, AND J. W. Alexander. Thoracolumbar kyphoscoliosis and compression fracture of a thoracic vertebra in a captive bottlenose dolphin (*Tursiops truncatus*). *Aquatic Mammals* 30: 275-278, 2004.
- Wells, R.S. and M.D. Scott. Seasonal incidence of boat strikes on bottlenose dolphins near Sarasota, Florida. *Marine Mammal Science* 13:475-480, 1997.



Figure 1. FB99, a female resident bottlenose dolphin (*Tursiops truncatus*), in Sarasota Bay, Florida displaying congenital scoliosis. (a) Slight “hump” seen ventral to the dorsal fin. (b) Slight curvature of peduncle at level of genital/anal slit. (c) Skeletal preparation showing the extent of the congenital deformities. Photo 1a was taken by the Chicago Zoological Society’s Sarasota Dolphin Research Program under NMFS scientific research permit #522-1569 Laboratory photos were taken by Mote Marine Laboratory’s Stranding Investigations Program under their Stranding Agreement.

during rehabilitation, treatment is possible, however the methods are sparse in peer reviewed literature. Rhinehart et al. 2000 discusses the treatment of a live-stranded common dolphin that was “bent” upon admittance. Treatments included myofacial massage and range of motion, coupled with neuromuscular electric stimulation, vitamin E/Selenium injections, trigger-point release, acupuncture, and daily positional release therapy that appeared to resolve the scoliosis. During rehabilitation, especially when a dolphin is unable to swim unassisted, this condition can occur

acutely and if aggressively treated with physical therapy, the condition can be reversed (F. Townsend, personal communication). While the peer reviewed literature is scarce for cetaceans, there have been rehabilitation and captive care facilities that have documented some success using cold laser therapy as treatment of scoliosis in dolphins (F. Townsend, L. Staggs, personal communication/Gulf World press release).

Zoonotic potential

Not applicable.

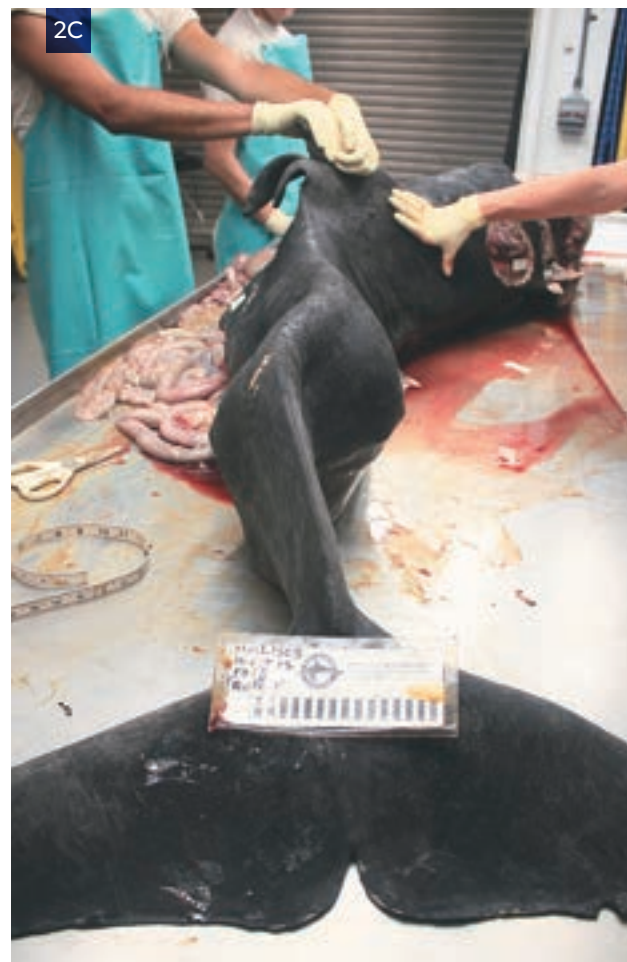
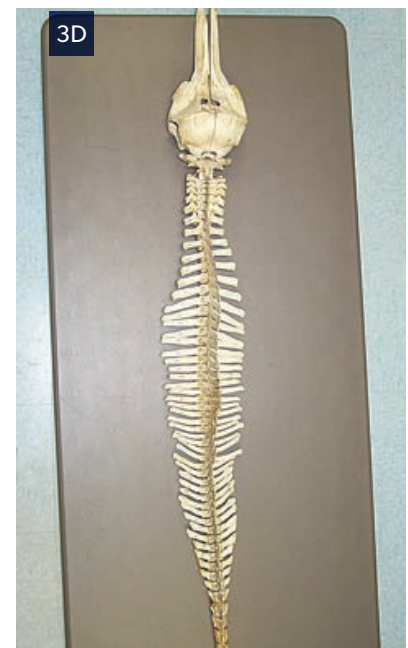
Figure 2. FB78, a male resident bottlenose dolphin (*Tursiops truncatus*), documented with scoliosis prior to suffering and recovering from a boat-strike in 1983, and died in 2015. (a) Distinct “s” curve of the peduncle. (b) Lateral view demonstrating the concavity of the peduncle. (c) Carcass upon recovery showing the “s” curve (d) The peduncle after flensing showing no obvious signs of congenital defects (no hemi-vertebrae, no obvious segmentation defects). Photo 2a and 2b taken by the Chicago Zoological Society’s Sarasota Dolphin Research Program under NMFS scientific research permits #15543 and #522-1569, respectively. Laboratory photos were taken by Mote Marine Laboratory’s Stranding Investigations Program under their Stranding Agreement.



*MML0004, a female common dolphin (*Delphinus delphis*) rehabilitated at Mote Marine Laboratory. (a) Acute scoliosis developed during rehabilitation. (b) Neuromuscular electric stimulation of affected area. (c) Necropsy photo showing the slight “bend,” without any obvious skeletal pathology. (d) Prepared skeleton confirming gross observation of no skeletal pathology. Laboratory photos were taken by Mote Marine Laboratory’s Dolphin and Whale Hospital and Stranding Investigations Program under their Stranding Agreement.*

SQUAMOUS CELL CARCINOMA

Molly Martony and Hendrik Nollens.

Clinical Presentation

Squamous cell carcinoma was first reported in the skin of a wild striped dolphin, and since then the neoplasm has been documented in beluga and various small cetaceans.¹⁻⁴ The oral cavity is typically affected with lesions associated with the floor of the mouth, frenulum, or tongue, although occurrences in the upper lip and hard palate have been described.^{2,5} Gross features are characterized by erythematous, singular to multifocal, irregular to smoothly marginated, flat to raised, papillomatous or non-healing ulcerative lesions. The masses or lesions are typically slow-growing however extensive local invasion can be seen with advanced disease and systemic metastasis is possible.⁶ Animals are often asymptomatic until late stages of the disease in which oral discomfort, local or systemic spread may contribute to anorexia. Ante-mortem staging of the disease may include ultrasonographic evaluation of the superficial cervical lymph nodes to monitor for regional spread, as evidenced by atypical node characteristics.

Histopathology

Biopsy and histopathologic confirmation are required for definitive diagnosis, as gross lesions may appear similar to papillomas or benign hyperplastic growths. Early lesions may appear benign histologically, however later malignant transformation is possible.^{6,7} Identification of atypical squamous cells characterized as pleomorphic with mitotic figures and abnormal keratinization is definitive for squamous cell carcinoma.⁸ Squamous cells may have abundant eosinophilic cytoplasm, prominent intercellular bridges, with partial keratinization, and

large round to oval vesicular nuclei with one or more prominent nucleoli of varied size.⁵ Squamous cells are arranged in nests and cords within variable desmoplasia and may have regions of keratin pearl formation and necrosis. The early disease form may be characterized as carcinoma in situ confined to the epidermis or mucosa with subsequent invasion into the dermis or submucosa followed by local and regional metastasis. Although some early lesions resemble papillomas histologically, it is important to note that a definitive etiologic agent has not been confirmed.

Treatment

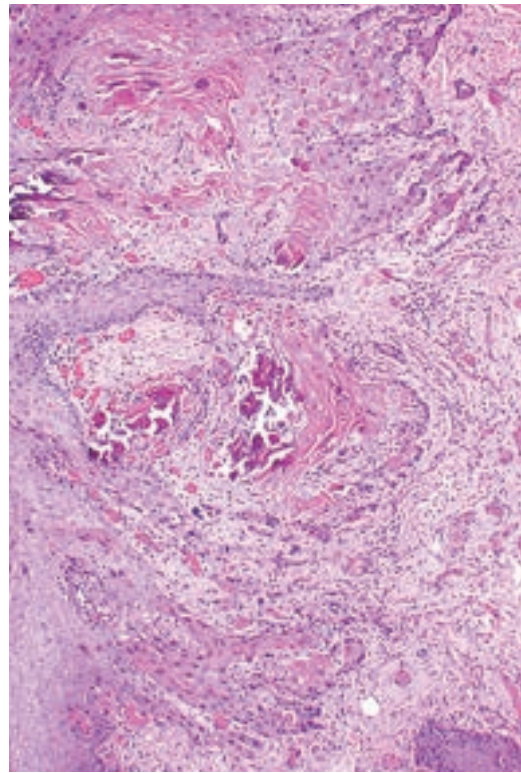
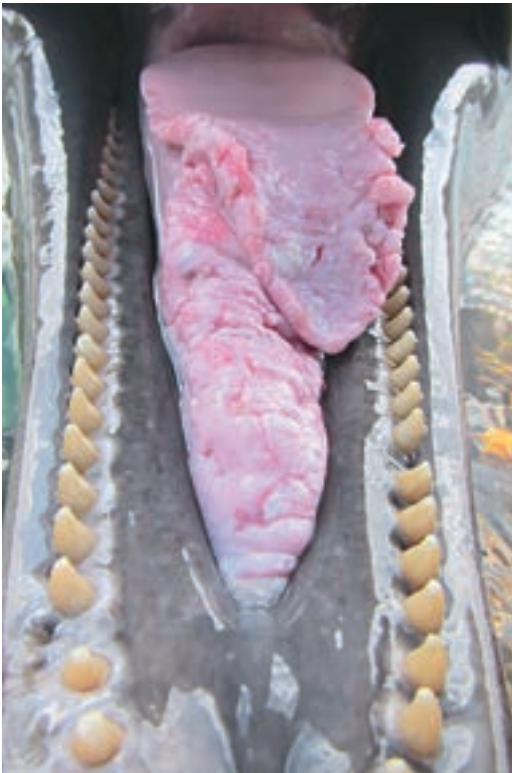Multiple medical and surgical interventions have been utilized with varying degrees of success in marine mammals including surgical excision, cryotherapy, laser therapy, brachytherapy, intralesional chemotherapy (carboplatin), topical immunomodulators, radiation therapy, and piroxicam as a sole agent or in combination with doxycycline.^{2,3,8-10} Currently surgical excision of early lesions with regional anesthesia or advanced lesions under general anesthesia appear most effective in managing oral squamous cell carcinomas. A course of piroxicam (0.1 mg/kg per os q 5-7 days, titrated to the lowest effective dose or frequency) prior to surgery may be effective in reducing lesion size prior to surgery. Surgical excision may improve the quality and length of life in select cases, however it is not yet clear if surgical intervention can be curative.

Acknowledgments

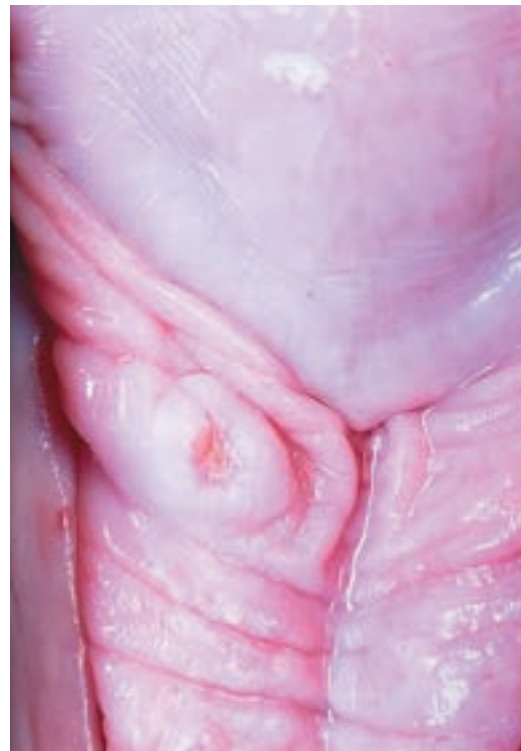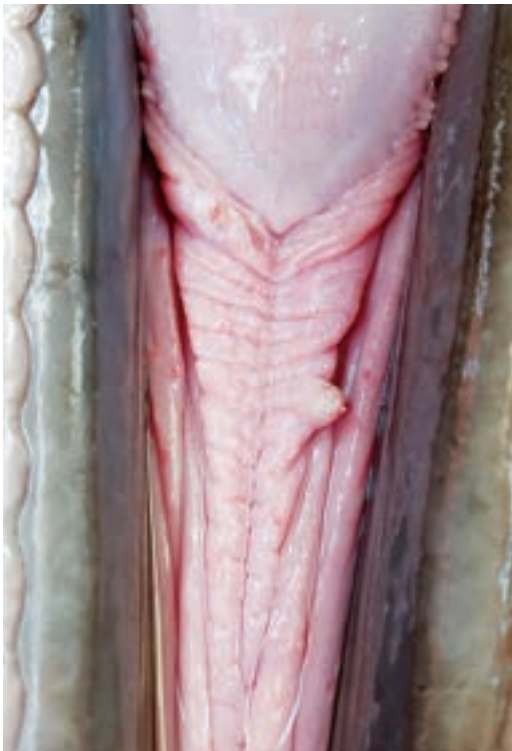This is a SeaWorld Parks and Entertainment technical contribution number 2019-1.

REFERENCE

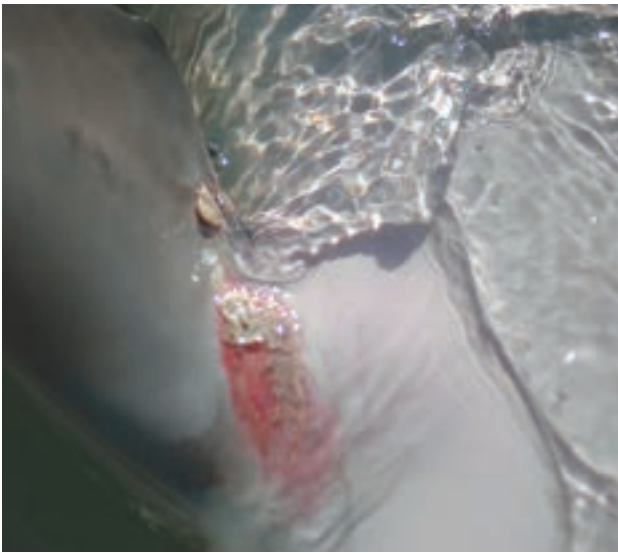
- Calada N, M Domingo. Squamous cell carcinoma of the skin in a striped dolphin (*Stenella coeruleoalba*). *European Research on Cetaceans*. 1990;4:114-115.
- Dover SR. Laser as a treatment for squamous cell carcinoma in a Pacific white sided dolphin. *International Association of Aquatic Animal Medicine*. 1994; 25:151.
- March DT, Blyde DJ, Begg AP, Taylor DP, McClure V. Piroxicam and doxycycline treatment for an oral squamous cell carcinoma in an inshore bottlenose dolphin (*Tursiops aduncus*). *Australian Veterinary Journal*. 2016;94(6):203-207.
- Newman S. Review article: marine mammal neoplasia: a review. *Vet Pathol*. 2006;43:865-880.
- Renner MS, Ewing R, Bossart GD, Harris D. Sublingual squamous cell carcinoma in an Atlantic Bottlenose dolphin (*Tursiops truncatus*). *Journal of Zoo and Wildlife Medicine*. 1999;30(4):573-576.
- Bossart G D. Orogenital neoplasia in Atlantic bottlenose dolphins (*Tursiops truncatus*). *Aquatic Mammals*. 2005;31(4):473-482.
- Bossart GD, Fair P, Schaefer AM, Reif SR. Health and environmental risk assessment project for the bottlenose dolphins *Tursiops truncatus* from the southeast USA. I. Infectious disease. *Diseases of Aquatic Organisms*. 2017;125:141-153.
- McKinnie CJ, Dover SR. Diagnosis and treatment of lingual carcinoma in an Atlantic bottlenose dolphin (*Tursiops truncatus*). *International Association of Aquatic Animal Medicine Proceedings*. 2003;34:164-165.
- McKinnie CJ, Dover SR, Ogilvie G, Bossart GD. Treatment of oral squamous cell carcinoma in an Atlantic Bottlenose Dolphin (*Tursiops truncatus*). *International Association of Aquatic Animal Medicine Proceedings*. 2001;37-28.
- McKinne CJ, Dube S, Fitzgerald RB, Conant J, French B, Lederer JL. Permanent i-125 seed implant in the treatment of squamous cell carcinoma in an Atlantic bottlenose dolphin (*Tursiops truncatus*). *International Association of Aquatic Animal Medicine Proceedings*. 2005:71-72.



Gross and histopathologic images from a 37 year old female bottlenose dolphin with oral squamous cell carcinoma associated with the tongue and frenulum. The photomicrograph (10X) demonstrates cellular dysplasia, dyskeratosis, and subsequent invasion into the submucosa. Multifocal regions of necrosis and mineralization (dark magenta) are also evident. (Images courtesy of SeaWorld Parks and Entertainment)



Gross images from a 13 year old male bottlenose dolphin diagnosed with oral squamous cell carcinoma. Two confirmed neoplasms (carcinoma in situ) are associated with the frenulum, the caudal lesion appears raised and ulcerated, while the rostral growth appears papillomatous. (Images courtesy of SeaWorld Parks and Entertainment)



AXILLARY BURNS

Forrest I. Townsend, Jr.

These lesions are uncommon today. Especially, during early transports of cetaceans, if care was not taken to assure the axillary space was kept cool. Severe thermal type burns occurred (*Fig 1*). These type wounds required long recovery periods and can result in permanent depigmentation of the axilla (*Fig 2*). Any time cetaceans are out of water for transportation, examination or procedures, care should be taken to prevent this.



Photo Credit: Dr. Forrest Townsend



NMFS Scientific Research
Permit No. 779-1633-02
Photo Credit NOAA



MMPA/ESA Permit No. 18786-1
Photo Credit NOAA

BIRTH MARKS

Forrest I. Townsend, Jr.

These distinct black pigmented areas of skin are very interesting. One case from Orange Beach, Alabama was present since birth (*Fig 1*). Another similar case (*Fig 2*) and smaller birthmark on the ventral fluke (*Fig 3*).



Photo credit Dolphin Quest. Bermuda Government permit No. SP160401r



Photo credit Dolphin Quest

DEEP WATER SQUID BITE WOUNDS

Jay Sweeney

Deep diving offshore Bottlenose dolphins in Bermuda (diving down to 3,300 ft.) encounter large squid (approximately 5 to 15 kg). As the dolphins seize the squid by the mantle, the squid sometimes are able to reach around and bite the dolphin at the gape of the jaw and even further aft, leaving deep puncture scars (see photos). To avoid these bites, the dolphins are able to shake the squid to decapitate it before bites can be done. In the photo is a squid head that came to the surface in proximity to a group of dolphins that were foraging in 2,500 ft. of water depth.



Photo credit: Forrest Townsend

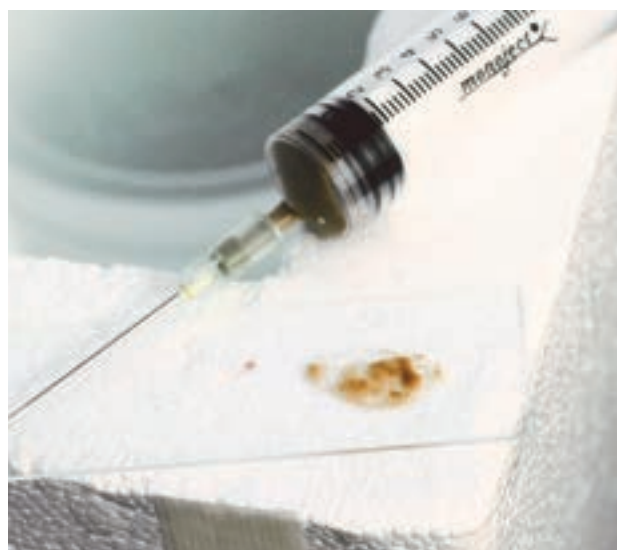

Photo credit: Forrest Townsend

HAIR FOLLICLE INFLAMMATION

Forrest I. Townsend, Jr.

Inflammation/Infection of the rostral hair follicles can occur (*Fig 1*) and the blocked follicle was full of a sebaceous material (*Fig 2*).



Photo credit: Dolphin Quest

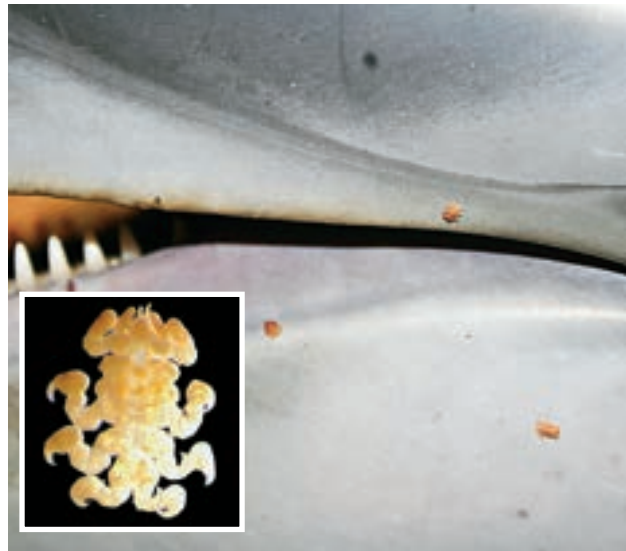


Photo credit: Dolphin Quest

REMORA WOUNDS

Jay Sweeney

My experience with remora “marks” are with smaller remora that create parallel “rail road-like” tracts that migrate caudally along the dolphin’s skin. However, in the offshore Atlantic dolphins, much larger remora cause remarkable skin lesions. These photos portray a large ramora attached to the dorsal fin (*Fig 1*). This results in rather large superficial wounds on the dorsal fins (*Fig 2*).



WHALE LICE

Photo Credit: Fundacion Oceanografic

Inset Photo Credit: Fundacion Oceanografic

Manuel Garcia

Cyamids (*Cyamidae*). Whale lice are parasitic amphipods generally found in clusters confined in small anatomic superficial areas of the skin (including eyes, blowhole, mouth, etc) where water flow is reduced. They attach to the host using clawed legs and feed on skin. Cyamids have a life cycle with all life stages over the cetacean host. Host transmission is due to direct contact between individuals. High infestation densities are associated to whale debilitation/sickness or immunocompromise. *Image: Syncyamus aequus over the blowhole (left) and side of the mouths skin with an insert of the organism. (Stenella coeruleoalba). Image courtesy of Universitat de Valencia*



The first of its kind, this field reference guide features more than one hundred and ninety colored photographs and discusses thirty-seven different conditions. Many of these gross lesions are obvious to the experienced observer; however, a major objective of this work is to help stranding organization volunteers, individuals working in wild dolphin photo identification and veterinarians new to this field to recognize these lesions and diseases. This Atlas is the work of thirty-one contributors, the majority being international recognized marine mammal veterinarians and biologists with years' of experience in marine mammal studies.